

This study aimed to evaluate serum level of sCXCL16 in patients with juvenile SLE (jSLE) for possible value of its estimation in assessing the disease activity and the extent of the disease.

Methods Twenty seven patients with jSLE and twenty healthy controls were included. Demographic and clinical features of the patients were recorded. Disease activity was assessed using the SLE Disease Activity Index (SLEDAI). The serum levels of sCXCL16 were determined by Eliza and correlated with clinical and laboratory parameters and with SLEDAI. Renal biopsy was done to all patients.

Results The serum levels of sCXCL16 in jSLE patients were higher than controls ($p < 0.001$), they were also significantly higher in patients with alopecia or malar rash than other jSLE. Positive correlation was identified between serum levels of sCXCL16 and SLEDAI score. There was a significant positive correlation between sCXCL16 levels and severity of lupus nephritis as assessed by renal biopsy. Serum levels of sCXCL16 were positively significantly correlated with the 24 hour urine protein, ANA, SBR, DBP AND ESR 1st hour. Serum sCXCL16 level was significantly negatively correlated with C3 serum level.

Conclusions Soluble CXCL16 could become a useful serological marker of disease activity and severity of renal involvement in jSLE patients.

134 AN UNUSUAL CASE OF PAEDIATRIC LUPUS WITH ISOLATED RETINAL INVOLVEMENT

¹A Jindal*, ²V Gupta, ¹S Suri, ¹A Rawat, ¹A Gupta, ¹S Singh. ¹PGIMER, Paediatrics, Chandigarh, India; ²PGIMER, Ophthalmology, Chandigarh, India

10.1136/lupus-2017-000215.134

Background and Aims Eye involvement in SLE is seen in around one third of patients. Retinal involvement is an uncommon but potentially vision threatening complication.

Methods To report the case of a young boy with isolated retinal involvement as the only manifestation of lupus.

Results A 9 year old previously healthy boy presented with complaints of fever, vomiting, seizures and alteration of sensorium. He had signs of raised intracranial pressure and rest of the examination was unremarkable (Investigations in Table 1 and 2). He was managed as a case of viral meningo-encephalitis though his CSF examination and neuroimaging revealed no abnormality. He was incidentally detected to have cotton wool

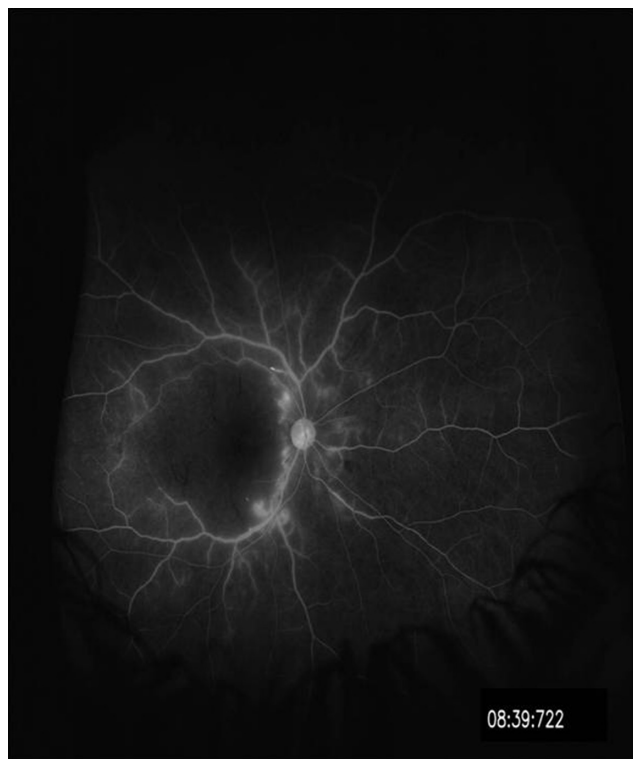
Abstract 134 Table 2

Investigations	Result
CSF	
Microscopy	No cells seen
Sugar (mg/dl)/protein (mg/dl)	102/91
Gram stain and AFB stain	Negative
TB PCR	Negative
Culture	Sterile
HSV DNA PCR	Negative
IgM Mycoplasma serology	Negative
IgM Leptospira serology	Negative
IgM Rickettsia serology	Negative
IgM dengue serology	Negative
Serum widal	Negative
Peripheral smear for malaria antigen	Negative
HIV ELISA	Negative
IgM EBV-VCA	negative
Mantoux	0 mm
Chest X-ray	Normal
Gastric lavage for AFB stain (3 samples)	negative
Urine microscopy (3 times)	No RBCs, protein- nil
ANA (done twice, IIF using Hep2 cells)	4+ speckled
C3(mg/dL)	183 (normal range: 50-150)
C4 (mg/dL)	35 (normal range: 20-50)
Anti ds DNA antibodies	Negative
Immunoblot for extractable nuclear antigen (ENA)	negative
Direct Coombs test	Negative (both anti IgG and anti C3d)
Skin biopsy for lupus band	No immune deposits
Antiphospholipid antibodies	Negative

spots in both eyes. After recovering from acute illness, he was also noted to have low vision in both eyes (light perception at 3 feet) Subsequently, a fundus fluorescein angiography was

Abstract 134 Table 1 Laboratory investigations

Investigations	Day 1	Day 3	Day 5	Day 7	Day 10	Day 20
Haemoglobin (gm/L)	91	91	105	81	72	76
WBC counts ($\times 10^3$ cells/ μ L)	3.7	3.8	6.6	4.2	5.1	8.6
Differential counts (P/L/M/E)	63/27/9/1	73/26/6/1	78/16/4/2	63/29/8/0	78/16/4/2	68/30/1/1
Absolute lymphocyte counts ($\times 10^3$ cells/ μ L)	1.0	1.0	1.0	1.2	0.8	2.6
Platelet counts ($\times 10^3$ / μ L)	169	148	108	73	107	570
AST/ALT (U/L)	53/46	138/61	195/65	147/49	146/56	57/44
Urea (mg/dL)	34	18	34	44	19	25
Creatinine (mg/dL)	0.7	0.7	1.2	0.9	0.6	0.4



Abstract 134 Figure 1

done that revealed capillary 'drop-out', vessel wall staining and leakage of dye. (Figure 1) He had antinuclear antibodies (4+ speckled pattern). A diagnosis of SLE with isolated retinal involvement (vasculopathy) was considered. In view of severely impaired visual acuity, he was managed with injection cyclophosphamide (followed by maintenance mycophenolate mofetil) and pulse methylprednisolone (followed by oral prednisolone). One year on follow up, his visual acuity has improved to 6/60 in both eyes. Repeat FFA revealed significant decrease in the non perfused areas of retina.

Conclusions Eye involvement in paediatric lupus is underrecognized entity and may need aggressive therapy.

135

SKIN PEELING AND IRRITABILITY IN A YOUNG BOY WITH SYSTEMIC LUPUS ERYTHEMATOSUS- IS THERE AN OVERLAP WITH KAWASAKI DISEASE?

A Jindal*, D Suri, A Gupta, A Rawat, S Singh. PGIMER, Paediatrics, Chandigarh, India

10.1136/lupus-2017-000215.135

Background and Aims Juvenile systemic lupus erythematosus (SLE) and Kawasaki disease can have several overlapping clinical and laboratory manifestations. But the co-occurrence of both disorders is extremely uncommon.

Methods To report the case of a young boy who had features of both SLE and KD

Results A 5 year old boy presented with fever for 2 months associated with photosensitive malar rash, oral ulcers and myalgias. On examination, he was irritable, had malar rash, a generalised erythematosus macular rash, oral ulcers, red and vertically cracked lips, redness of bulbar conjunctiva, cervical lymphadenopathy and hepatomegaly. Laboratory investigations are summarised in Table 1. All infectious disease workup was normal. He had hypocomplementemia, positive ANA, anti dsDNA and anti-nucleosome antibody. He was diagnosed as SLE and initiated on oral prednisolone. Fever subsided, transaminitis and leucopenia showed gradual recovery. One week later developed periungual skin peeling and he remained irritable. Laboratory investigations showed anaemia, thrombocytosis, persistently elevated ESR and high CRP (Table 1) A diagnosis of incomplete KD was proffered. He was given intravenous immunoglobulin (IVIG) (2 gm/kg), which led to prompt improvement in his irritability. He was initiated on aspirin (3 mg/kg/day) and continued on oral prednisolone. Aspirin was discontinued 6 weeks later after confirmation of normal coronary findings on echocardiography. Beau's lines were noticed in the finger nails at this time. At 3 months follow-up, he continues to remain well. Serum transaminases, platelet counts, ESR and CRP have normalised. (Table 1)

Conclusions Overlap of KD and SLE is extremely uncommon. (Table 2)

Abstract 135 Table 1 Laboratory investigations

Investigation Day of Admission	Hemoglobin (gm/L)	White blood cell count ($\times 10^9$ cells/L)	Differential counts (P/L/M/E)	Platelet counts ($\times 10^9$ /L)	ESR (mm in 1 st hr)	CRP (mg/L)	AST/ ALT (U/L)
Day 1	76	3.3	30/60/8/2	292	52	82	182/73
Day 5	70	4.1	21/69/9/1	269	83	-	816/287
Day 9	76	7.3	54/38/6/2	225	-	-	456/286
Day 21*	83	14.9	45/35/9	510	61	16	88/139
Day 60	100	13.6	49/41/9/1	400	40	4	36/45

*IVIg was administered on day 21