


# Relationship between retinal microvascular impairment and subclinical atherosclerosis in SLE

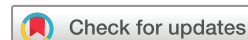Sara Ferrigno <sup>1</sup>, Paola Conigliaro,<sup>1</sup> Stefano Rizza,<sup>2</sup> Susanna Longo,<sup>2</sup> Carolina Nesi,<sup>3</sup> Federico Carlucci,<sup>3</sup> Alberto Bergamini,<sup>1</sup> Raffaele Mancino,<sup>3</sup> Carlo Nucci,<sup>3</sup> Massimo Federici,<sup>2</sup> Maria Sole Chimenti,<sup>1</sup> Massimo Cesareo<sup>3</sup>

**To cite:** Ferrigno S, Conigliaro P, Rizza S, *et al.* Relationship between retinal microvascular impairment and subclinical atherosclerosis in SLE. *Lupus Science & Medicine* 2023;**10**:e000977. doi:10.1136/lupus-2023-000977

► Additional supplemental material is published online only. To view, please visit the journal online (<http://dx.doi.org/10.1136/lupus-2023-000977>).

SF and PC contributed equally. MSC and MC contributed equally.

Received 17 June 2023  
Accepted 19 September 2023



© Author(s) (or their employer(s)) 2023. Re-use permitted under CC BY-NC. No commercial re-use. See rights and permissions. Published by BMJ.

<sup>1</sup>Rheumatology, Allergology and Clinical Immunology, Department of 'Medicina dei Sistemi', University of Rome Tor Vergata, Rome, Italy

<sup>2</sup>Department of 'Medicina dei Sistemi', University of Rome Tor Vergata, Rome, Italy

<sup>3</sup>Ophthalmology, Department of Experimental Medicine and Surgery, University of Rome Tor Vergata, Rome, Italy

**Correspondence to**  
Dr Sara Ferrigno; sara.ferrigno16@gmail.com

## ABSTRACT

**Objectives** Patients with SLE have higher cardiovascular (CV) risk compared with healthy controls (HC) and are characterised by accelerated atherosclerosis; intima media thickness (IMT), marker of subclinical atherosclerosis, is higher in patients with SLE than in HCs. Retinal microvascular impairment detected through optical coherence tomography angiography (OCTA) was investigated as a marker of systemic vascular involvement in SLE.

The aim of the study was to evaluate the relationship between retinal vascular impairment and IMT in SLE.

**Methods** Cross-sectional study recruiting patients with SLE and HCs. Data of the study population were collected. CV risk was evaluated through the American College of Cardiology/American Heart Association (ACC/AHA) guidelines, Framingham and QRESEARCH risk estimator V.3 (QRISK3) scores. Both groups underwent OCTA and carotid ultrasound with IMT assessment.

Statistical analysis was accomplished using Pearson/Spearman, t-test/Mann-Whitney or  $\chi^2$  test. Variables statistically significant at univariate regression analysis were tested in an age-corrected and sex-corrected multivariate regression model.

**Results** 43 patients with SLE and 34 HCs were recruited. Patients with SLE showed higher triglycerides ( $p=0.019$ ), Triglycerides-Glucose (TyG) Index ( $p=0.035$ ), ACC/AHA guidelines ( $p=0.001$ ), Framingham Risk Scores ( $p=0.008$ ) and a reduced superficial ( $p<0.001$ ) and deep ( $p=0.005$ ) whole retinal vessel density (VD) compared with HCs. In SLE univariate analysis, deep whole VD showed a negative correlation with IMT ( $p=0.027$ ), age ( $p=0.001$ ), systolic blood pressure ( $p=0.011$ ), QRISK3 Score ( $p<0.001$ ), Systemic Lupus International Collaborating Clinics Damage Index ( $p=0.006$ ) and apolipoprotein B ( $p=0.021$ ), while a positive correlation was found with female sex ( $p=0.029$ ). Age-adjusted and sex-adjusted multivariate analysis confirmed QRISK3 Score ( $p=0.049$ ) and IMT ( $p=0.039$ ) to be independent risk factors for reduced retinal VD.

**Conclusions** Patients with SLE showed lower retinal VD and higher CV risk indicators compared with HCs. Among patients with SLE, QRISK3 Score and IMT were found to be independent risk factors for retinal vascular impairment, suggesting a role of OCTA in evaluating preclinical CV involvement in SLE. Moreover, TyG Index could represent a biomarker of CV risk in patients with SLE compared with HCs.

## WHAT IS ALREADY KNOWN ON THIS TOPIC

- ⇒ Patients with SLE are characterised by a process of accelerated atherosclerosis, resulting from an interplay between traditional and disease-related cardiovascular (CV) risk factors.
- ⇒ Retinal subclinical alterations detected through optical coherence tomography angiography (OCTA) have been correlated with systemic involvement in SLE.
- ⇒ Recently, a correlation between intima media thickness (IMT) and OCTA in systemic diseases, such as hypertension and diabetes, has been detected.

## WHAT THIS STUDY ADDS

- ⇒ This is the first study evidencing a relationship between IMT, CV risk assessed through QRESEARCH Risk Estimator Score and retinal vascular impairment in SLE.
- ⇒ Moreover, it underlines the role of triglycerides and Triglycerides-Glucose Index in evaluating CV risk in patients with SLE compared with healthy controls.

## HOW THIS STUDY MIGHT AFFECT RESEARCH, PRACTICE OR POLICY

- ⇒ This study suggests that OCTA could represent a valid non-invasive instrument to evaluate CV involvement in SLE at its preclinical stage.

## INTRODUCTION

SLE is a complex, immune-mediated disease involving multiple organs and systems. Individuals with SLE have a 10-fold increased risk of developing cardiovascular (CV) events, with a 50-fold risk in women at reproductive age, compared with the general population, that can't be fully explained by the presence of traditional CV risk factors.<sup>1</sup> In fact, traditional Framingham Risk Score has proved to fail in predicting CV risk in patients with SLE, particularly in young women.<sup>2</sup> This increase in CV risk is the result of an interplay between traditional and disease-related risk factors, such as disease activity, disease duration, kidney involvement, antiphospholipid antibody positivity and corticosteroid

therapy.<sup>1</sup> A novel algorithm has recently been validated, the QRESEARCH Risk Estimator V.3 (QRISK3) Score, showing better accuracy in predicting CV risk in SLE compared with the Framingham Risk Score and the American College of Cardiology/American Heart Association (ACC/AHA) guidelines, particularly in younger patients, patients with chronic kidney disease and in those on regular steroid therapy.<sup>3</sup> Current studies demonstrate that patients with SLE are characterised by a process of accelerated atherosclerosis and have a twofold prevalence of atherosclerotic plaques compared with the general population.<sup>1</sup> Different immune and inflammatory mechanisms involved in SLE pathogenesis have been identified as responsible for an imbalance between vascular injury and vascular repair, leading to endothelial dysfunction.<sup>4</sup> Individuals with increased intima media thickness (IMT) carry a higher risk of developing carotid atherosclerosis. Accordingly, IMT acts as a marker of subclinical atherosclerosis. In recent studies, patients with SLE showed higher IMT and higher IMT progression in a 5-year follow-up compared with healthy controls (HCs).<sup>5,6</sup>

On the other side, SLE retinopathy can result from a vasculitic immune-complex mediated process, it is a marker of poor prognosis, and has been associated with disease activity and organ involvement.<sup>7</sup>

Optical coherence tomography angiography (OCTA) is a non-invasive technique for imaging the microvasculature of the retina and choroid. It has been investigated in the past for its ability to detect preclinical vascular damage in systemic diseases such as diabetes, arterial hypertension and chronic kidney disease.<sup>8</sup> A relationship between retinal microvascular alterations and CV risk profile was also underlined in patients with coronary artery disease, but further studies in this field are needed.<sup>9</sup>

Recently, subclinical retinal microvascular impairment evaluated through OCTA has been detected in patients with SLE compared with HCs.<sup>10</sup> Moreover, a correlation between retinal microvascular alterations, kidney function parameters and vascular lesions detected at kidney biopsy was assessed in a lupus nephritis cohort.<sup>8</sup>

A relationship between IMT and reduced OCTA retinal vascular density has been identified in systemic diseases, such as hypertension and diabetes.<sup>11,12</sup> Therefore, we hypothesised that retinal microvascularisation could reflect systemic vascular damage in SLE.

Aim of the study was to evaluate the relationship between retinal vascular impairment and carotid IMT in patients with SLE.

## MATERIALS AND METHODS

### Study population

This study was a monocentric, cross-sectional study, recruiting consecutive patients with SLE referring to the Rheumatology Clinic of the University of Rome Tor Vergata, Rome, Italy, between 1 January 2021 and 31 December 2022. SLE was classified according to the 2019 European League Against Rheumatism/American

College of Rheumatology (EULAR/ACR) classification criteria.<sup>13</sup> Inclusion criteria were: (1) Age range 18–80 years; (2) Best-corrected visual acuity (BCVA) >0.5 Logarithm of the Minimum Angle of Resolution (LogMAR).

Exclusion criteria were: (1) Coexistence of other rheumatic diseases, such as antiphospholipid syndrome, Sjogren's syndrome, systemic sclerosis, mixed connective tissue disease, rheumatoid arthritis; (2) Retinal toxicity due to antimalarials according to 2016 American Academy of Ophthalmology criteria<sup>14</sup>; (3) Primary ophthalmic pathology, presence of lens opacities, drusen-like deposits, focal atrophy, retinal pigment epithelium detachment, history of ocular trauma or surgery; (4) History of CV diseases, such as coronary artery disease, cerebrovascular disease, peripheral arterial disease and aortic disease; (5) History of diabetes; (6) History of uncontrolled arterial hypertension.

A population of HCs was also recruited at the Ophthalmology Clinic of the University of Rome Tor Vergata, Rome, Italy, comparable for age and sex to patients with SLE.

### Ophthalmological evaluation

A standard LogMAR chart was used to determine the BCVA in each eye to test central visual acuity according to the Early Treatment Diabetic Retinopathy Study (ETDRS) protocol. All subjects underwent Goldmann applanation tonometry to assess the intraocular pressure using a Haag-Streit tonometer with a slit lamp. Ocular fundus examination by biomicroscopic examination at slit-lamp and high-resolution colour retinography (Canon CF-1 digital retinal camera, Canon) was performed in order to define presence or absence (1/0) and grade of lupus retinopathy.<sup>15</sup>

Using spectral domain-optical coherence tomography (SD-OCT; Spectralis, Heidelberg Engineering, Heidelberg, Germany), all participants underwent the 'Posterior Pole' (PP) scanning protocol. The image alignment eye-tracking software (TruTrack; Heidelberg Engineering GmbH) was employed to acquire volumetric retinal scans, consisting of 61 single axial scans (scanning area: 30° × 25°), focused on the fovea, with a fovea-to-disc inclination of 7°. The thickness measurements for total retinal (retina), retinal nerve fibre layer (RNFL) and ganglion cell layer (GCL) were obtained through Spectralis automated segmentation (software V.6.0).

The instrument divides the macular area into nine specific regions, defined by a grid called ETDRS (name related to a study conducted in the past on diabetic macular oedema). The inner circle has 3mm of diameter and contains the IS (inner superior), IT (inner temporal), II (inner inferior) and the IN (inner nasal) areas. The outer circle, reported in red, has 6mm of diameter and is divided into the OS (outer superior), OT (outer temporal), OI (outer inferior) and the ON (outer nasal) areas. The central section is represented by the foveal area (F)<sup>16</sup>

Pupil dilation was achieved using 0.5% tropicamide and 10% phenylephrine eye drops (Visumidriatic Fenilefrina, Visufarma) before performing all SD-OCT scans. An internal fixation target was used during PP scans, and participants were instructed to fixate on this central target throughout the scanning process. Only high-quality scans were considered for the analysis, characterised by a signal quality score >25 on a scale from 0 (poor quality) to 40 (excellent quality).

We also evaluated the presence of retinal ischaemic perivascular lesions (RIPLs), focal atrophy areas detected in the inner nuclear layer at SD-OCT scans, which represent anatomical markers of prior retinal ischaemic infarcts.<sup>17</sup>

### Optical coherence tomography angiography

OCTA technology uses laser light reflectance of the surface of moving red blood cells to accurately depict vessels through different segmented areas of the eye. Same tissue area is repeatedly imaged, differences analysed between scans, allowing to detect zones containing high flow and zones with slower or no flow.<sup>18</sup> OCTA was performed by the Avanti AngioVue Imaging System (Optovue, software V.2018.1.0.22, Fremont, California, USA), using the Angio Retina mode 6×6mm volumetric scan in the macular area with an A-scan rate of 70 kHz, a light source centred on 840 nm and a bandwidth of 45–50 nm as previously shown.<sup>10</sup> Retinal layer segmentation was checked for artefacts by the same experienced operator. Images with quality >8 have been considered for the study.<sup>10</sup>

Vessel density (VD) was evaluated and expressed as % both in superficial and deep retinal plexi, each of these analysing the whole image, the parafoveal and the foveal regions. The fovea avascular zone area (mm<sup>2</sup>) and perimeter (mm) of the two groups were also assessed.

### Rheumatological evaluation

All patients with SLE underwent a rheumatological evaluation. Disease activity and cumulative organ damage were evaluated using the Systemic Lupus Erythematosus Disease Activity Index 2000 (SLEDAI-2K)<sup>19</sup> and Systemic Lupus International Collaborating Clinics Damage Index (SLICC-DI), respectively.<sup>20</sup>

Disease duration, history of antirheumatic treatment, including hydroxychloroquine (HCQ), prednisone (PDN, cumulative doses), evaluating both current use and cumulative doses, immunosuppressive drugs (azathioprine, methotrexate, cyclosporine, mycophenolate, cyclophosphamide) and biologic treatment (rituximab and belimumab), were assessed.

The following laboratory parameters were tested: presence of disease characterising autoantibodies ever, such as anti-double strand DNA (anti-dsDNA) antibodies (IU/mL, over twice the upper limit of normal) by commercial Enzyme-Linked Immunosorbent Assays (ELISA), anticardiolipin antibodies, IgG ≥40 IgG phospholipid (GPL) units, IgM ≥40 IgM phospholipid (MPL) units, by commercial ELISA (Inova Diagnostics, San Diego, California, USA), anti-β2-glycoprotein I antibodies, IgG

≥40 GPL units; IgM ≥40 MPL units, by commercial ELISA (QUANTA Lite™; Inova Diagnostics) and ANA ≥1:160 by direct immunofluorescence (QUANTA Lite™; Inova Diagnostics), presence of lupus anticoagulant by dilute Russel's viper venom time and confirmatory mixing studies if prolonged and plasmatic complement components C3 and C4 (normal values: 83–193 mg/dL and 15–57 mg/dL, respectively), measured by immunoturbidimetry.

### CV risk assessment

We collected patients' and controls' clinical, biochemical and anthropometric data, including sex, age, smoking habit (current or former), body mass index (BMI), and systolic and diastolic blood pressure (BP). BP was measured in the dominant arm in the sitting position with a standard sphygmomanometer cuff. Laboratory markers of CV risk were evaluated, including total cholesterol, high-density lipoprotein (HDL) and triglycerides (TG) detected by enzymatic colorimetric assay.

Apolipoprotein B-100 (APO-B) and Triglycerides-Glucose (TyG) Index were calculated using the appropriate algorithms.<sup>21 22</sup> Ten-year CV risk of the study population was also estimated using the Framingham Risk Score<sup>23</sup> and the ACC/AHA pooled cohort equation<sup>24</sup> for patients SLE and HCs. Patients included in the ACC/AHA assessment required an age range between 40 years and 79 years. Moreover, the QRISK3 Score was calculated for patients with SLE.<sup>3</sup>

### Carotid artery examination

All the participants performed a carotid ultrasound to calculate carotid IMT, as previously described.<sup>25 26</sup> The anterior, lateral and posterolateral projections were used to image longitudinally right and left common carotid arteries. At each projection, three determinations of IMT were made at 2 cm proximal to the bulb, at the site of the greatest thickness. The values at each site were averaged, and the greatest value of the averaged IMT was used for each individual. Two different blinded experts (SR and SL) read all images and measurements with replicate readings performed on 5% of the cohort participants with results indicating an intraclass correlation value of 0.93. IMT was not assessed in patients showing carotid plaques, defined as a localised thickening of >1 mm and at least a 100% increase in thickness compared with adjacent arterial wall segments. To perform carotid emanation we used the Esaote Mylab System (Ref 101620000) using a VF 13e5 linear array transducer.

### Statistical analysis

Quantitative data are expressed as mean±SD and categorical variables are expressed as number (percentage) of participants. To test the normality of the data sets, the D'Agostino and Pearson omnibus tests were used.

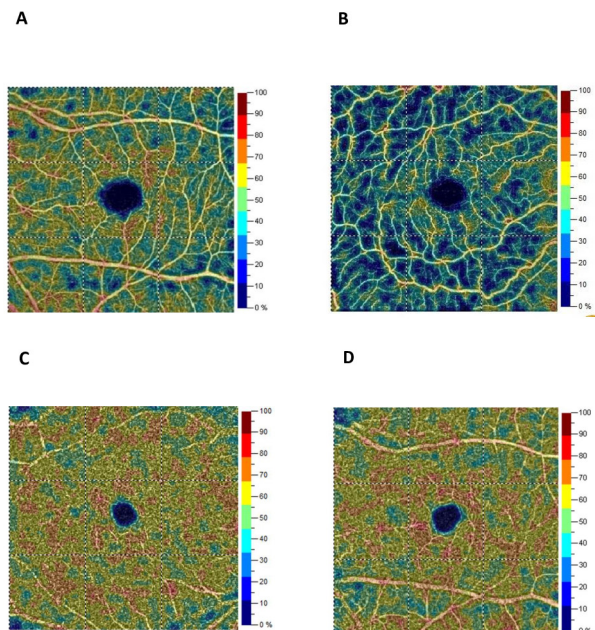
Categorical variables were compared using the  $\chi^2$  test. Continuous variables were compared using the parametrical unpaired *t*-test or the non-parametrical Mann-Whitney U test, when appropriate. The significance of



**Table 1** Clinical, biochemical and anthropometric characteristics of the study population

	SLE (n=43)	HCs (n=34)	P value
Age, years	51.6±14.5	51±10.3	0.731
Sex (female)	39 (90.7)	29 (85.2)	0.216
Disease duration, months	193.9±135.3	NA	NP
C3, mg/dL	95.3±21	NA	NP
C4, mg/dL	20.5±8.7	NA	NP
Anti-dsDNA abs (positivity)	9 <sup>21</sup>	NA	NP
Antiphospholipid abs (positivity ever)	15 (34.8)	NA	NP
SLEDAI-2K	2.7±2.4	NA	NP
SLICC-DI	1.4±1.4	NA	NP
Nephritis (yes)	19 (44)	NA	NP
PDN (yes)	26 (60.4)	NA	NP
PDN cumulative dose, g	20.2±18.3	NA	NP
HCQ (yes)	10 (23.2)	NA	NP
HCQ cumulative dose, g	1099.5±950.5	NA	NP
Smoker (active or former)	12 (28)	10 (29.4)	0.522
BMI	24.9±4.6	24.3±3.7	0.438
Systolic BP, mm Hg	116.5±14.5	116±15.9	0.664
Diastolic BP, mm Hg	71.2±11.3	67.5±15.8	0.125
Fasting glucose, mg/dL	88±24.6	90.6±8.6	0.409
HbA1c, mmol/mol	36.7±6.3	34.5±7.3	0.105
Total cholesterol mg/dL	186.4±44.6	191.9±25.4	0.429
HDL cholesterol, mg/dL	58.3±21.4	60.6±11.1	0.693
LDL cholesterol, mg/dL	105.4±38.9	117.2±27.5	0.056
TG, mg/dL	105.3±46.2	84.5±46.4	<b>0.019</b>
APO-B	93±27	97.6±21.6	0.272
TyG index	8.3±0.5	8.1±0.5	<b>0.035</b>
Framingham Score	9.9±6.5	6.9±5.4	<b>0.008</b>
ACC/AHA ASCVD Score	5.3±5	2.8±1.5	<b>0.001</b>
QRISK3 Score	11.5±8.0	NA	NP
IMT, mm	5.717±1.355	5.78±1.152	0.789
Superficial whole en face VD, %	50.1±5.6	53.0±2.3	<b>&lt;0.001</b>
Superficial fovea VD, %	21.3±9.5	22.6±7.3	0.691
Fovea thickness (µm)	255.3±21.5	257.9±23.4	0.516
Superficial parafovea density, %	53.6±4.9	71.0±27.5	0.118
Parafovea thickness (µm)	317.9±23.6	320.5±19.4	0.508
Deep whole en face VD, %	55.4±7.0	58.6±5.4	<b>0.005</b>
Deep fovea VD, %	39.2±8.2	41.1±7.8	0.184
Deep parafovea VD, %	59.0±5.0	60.7±4.6	<b>0.046</b>
FAZ (mm <sup>2</sup> )	0.26±0.10	0.25±0.10	0.607
FAZ perimeter (mm)	1.94±0.41	1.93±0.43	0.828

Data are shown as numbers (%) or means±SD. Values of  $p < 0.05$  were considered statistically significant and are highlighted in bold. ACC/AHA, American College of Cardiology/American Heart Association; Anti-dsDNA, anti-double strand DNA; APO-B, apolipoprotein B; ASCVD, atherosclerotic cardiovascular disease; BMI, body mass index; BP, blood pressure; FAZ, fovea avascular zone; HbA1c, glycated haemoglobin; HCQ, hydroxychloroquine; HCs, Healthy Controls; HDL, high-density lipoprotein; IMT, intima media thickness; LDL, low-density lipoprotein; NA, not applicable; NP, not performed; PDN, Prednisone; QRISK3, QRESEARCH risk estimator version 3; SLEDAI-2K, Systemic Lupus Erythematosus Disease Activity Index 2000; SLICC-DI, Systemic Lupus International Collaborating Clinics Damage Index; TG, Triglycerides; TyG, triglycerides-glucose; VD, vessel density.



**Figure 1** Optical coherence tomography angiography (OCTA) colour-coded images of superficial retinal plexus in a healthy subject (A) and a patient with SLE (B). Deep retinal plexus in a healthy subject (C) and a patient with SLE (D).

any correlation was determined by the Pearson correlation test or Spearman's rank correlation coefficient, when appropriate. Univariate regression analysis was performed between the selected dependent variable and the study covariates. Variables with statistical significance were further tested in a multivariate regression model corrected for age and sex. Values of  $p < 0.05$  were considered statistically significant.

Analyses were performed using IBM SPSS Statistics V.27.0 for Windows.

## RESULTS

Eighty-six ( $n=86$ ) eyes of 43 patients with SLE ( $n=43$ ) and 68 eyes ( $n=68$ ) of 34 controls ( $n=34$ ) were examined. **Table 1** shows clinical, biochemical and anthropometric parameters of the two cohorts. Mean disease duration in patients with SLE was  $193.9 \pm 135.3$  months, mean SLEDAI-2K was  $2.7 \pm 2.4$ , corresponding to low disease activity, and mean SLICC-DI was  $1.4 \pm 1.4$ . Nine patients were positive for anti-dsDNA (21%) at the time of the visit, while 15 patients had a history of antiphospholipid antibodies positivity (38.4%).

Traditional CV risk factors such as smoking habit, BMI and BP measurements were similar between patients and controls. Patients with SLE displayed higher levels of TG compared with those in HCs together with higher TyG Index, while total cholesterol, HDL, low-density lipoprotein, APO-B, fasting glucose and glycated haemoglobin (HbA1c) levels were comparable between the two groups.

Moreover, the 10-year CV risk estimated through the Framingham Risk Score and the ACC/AHA pooled cohort equation was higher in patients with SLE than in HCs. ACC/AHA was assessed in 28 patients with SLE

(65.1%) and 22 HCs (64.7%) according to the required age range. IMT assessed by carotid ultrasound was similar between patients with SLE and HCs.

According to SLE treatment, 33 (76.7%) patients were on HCQ, 22 (51%) were assuming a PDN daily dose  $\geq 5$  mg, 28 (65%) were under immunosuppressive treatment and 6 (14%) were on biologic therapy.

**Figure 1** displays OCTA colour-coded images of superficial (A–B) and deep (C–D) retinal plexi of an HC and a patient with SLE, respectively. According to OCTA data analysis, patients with SLE showed a significant reduction in superficial whole en face VD, deep whole en face VD and deep parafoveal VD compared with HCs. Other OCTA parameters were similar between patients SLE and HCs (**table 1**).

Ophthalmological evaluation revealed that 12 patients with SLE (27.9%) had evidence of lupus retinopathy, 4 mild (9.3%), 6 moderate (13.9%) and 2 at severe stage (4.6%) at fundus oculi examination and high definition colour retinography.

OCT data of patients with SLE and HCs are displayed in online supplemental table 1. Patients with SLE showed a reduced thickness compared with HCs in the following retinal segments: total retina IT, ON, IN and OI; GCL IT, IS, IN and II, while no significant differences were detected among RNFL data (online supplemental table 1).

According to OCT evaluation, retinal regions' thickness of the total retinal, RNFL and GCL layers was correlated with both IMT and QRISK3 score in patients with SLE, but no significant correlations were detected (data not shown).

Moreover, the presence of RIPLs in OCT scans was not identified in patients with SLE and HCs.

In the SLE population, the univariate regression model with deep whole en face VD selected as the dependent variable showed a significant negative correlation between deep whole image VD and IMT values, together with a significant negative correlation between deep whole image VD and age and systolic BP levels and APO-B, while a positive correlation was found with female sex. Moreover, results underlined a negative correlation between deep whole en face VD and both QRISK3 Score and SLICC-DI. No significant correlations were found between deep whole en face VD and the following parameters: smoking habit, BMI, diastolic BP, fasting glucose, HbA1c, total cholesterol, HDL, triglyceride levels, TyG Index value, disease duration, SLEDAI-2K Score, presence of anti-dsDNA and antiphospholipid antibodies, history of lupus nephritis, PDN and HCQ treatment (both cumulative and daily dose) (**table 2**).

Multivariate regression analysis, adjusted for age and sex, confirmed that IMT and QRISK3 Score were independently associated with a reduction of deep whole en face VD in patients with SLE (**table 2**).

**Table 2** Univariate and multivariate analyses models for deep whole en face density

	Univariate $\beta$ coefficient (CI 95%)	P value	Multivariate $\beta$ coefficient (CI 95%)*	P value
Age, years	0.167(−0.264 to −0.071)	<b>0.001</b>	NP	
Sex (female)	5.466 (0.571 to 10.360)	<b>0.029</b>	NP	
Disease duration, months	0.063 (−0.455 to 0.329)	0.746	NP	
Anti-dsDNA abs (positivity)	1.490 (−5.454 to 2.473)	0.456	NP	
Antiphospholipid abs (positivity ever)	3.606 (0.000 to 7.150)	0.061	NP	
SLEDAI-2K	0.466 (−1.094 to 0.163)	0.144	NP	
SLICC-DI	1.432 (−2.434 to −0.430)	<b>0.006</b>	0.632 (−1.694 to 0.431)	0.240
Nephritis (yes)	2.860 (−5.808 to 0.087)	0.057	NP	
PDN (yes)	1.269 (−4.250 to 1.711)	0.399	NP	
PDN (cumulative dose, g)	0.021 (−0.116 to 0.074)	0.658	NP	
HCQ (yes)	0.700 (−3.571 to 4.971)	0.745	NP	
HCQ (cumulative dose, g)	0.000 (−0.001 to 0.002)	0.740	NP	
Smoker (active or former)	2.040 (−1.307 to 5.387)	0.229	NP	
BMI	0.274 (−0.589 to 0.041)	0.087	NP	
Systolic BP (mm Hg)	0.131(−0.231 to −0.031)	<b>0.011</b>	0.060 (−0.162 to 0.041)	0.237
Diastolic BP (mm Hg)	0.112 (−0.241 to 0.017)	0.088	NP	
Fasting glucose (mg/dL)	0.028 (−0.041 to 0.097)	0.420	NP	
HbA1c (mmol/mol)	0.063 (−0.455 to 0.329)	0.746	NP	
Total cholesterol (mg/dL)	0.032 (−0.006 to 0.071)	0.100	NP	
HDL cholesterol (mg/dL)	0.034 (−0.114 to 0.046)	0.394	NP	
TG (mg/dL)	0.002 (−0.038 to 0.041)	0.938	NP	
APO-B (mg/dL)	0.072 (−0.011 to 0.133)	<b>0.021</b>	0.058 (−0.001 to 0.117)	0.079
TyG Index	3.930 (−7.668 to −0.193)	0.535	NP	
Framingham Score	1.068 (−4.496 to 2.361)	0.100	NP	
QRISK3 Score	0.342 (−0.515 to −0.168)	<b>&lt;0.001</b>	0.199 (−0.411 to 0.012)	<b>0.049</b>
IMT (mm)	0.012 (−0.023 to −0.002)	<b>0.027</b>	0.007 (−0.028 to −0.001)	<b>0.039</b>

\*Model adjusted for sex and age. Values of  $p < 0.05$  were considered statistically significant and are highlighted in bold.

Anti-dsDNA, anti-double strand DNA; APO-B, apolipoprotein B; BMI, body mass index; BP, blood pressure; HbA1c, glycated haemoglobin; HCQ, hydroxychloroquine; HDL, high-density lipoprotein; IMT, intima media thickness; NP, not performed; PDN, prednisone; QRISK3, QRESEARCH risk estimator version 3; SLEDAI-2K, Systemic Lupus Erythematosus Disease Activity Index 2000; SLICC-DI, Systemic Lupus International Collaborating Clinics Damage Index; TG, Triglycerides; TyG, triglycerides-glucose.

## DISCUSSION

In the present study, we evaluated for the first time the relationship between IMT and retinal microvascularisation assessed through OCTA in a SLE cohort, together with clinical and serological CV risk factors, compared with a group of HCs. We used the Framingham Risk Score and the QRISK3 Score to evaluate CV risk in SLE, in order to consider traditional and disease-related risk factors. An ACC/AHA pooled cohort equation was also evaluated in our population, since it is the current validated method to assess CV risk in the general population. However, the age limit required, due to its low reliability in patients under 40 years of age, excluded part of our SLE sample and prevented us from including it in the final analysis.

According to our results, patients with SLE showed a significant reduction in retinal VD, both in superficial

and deep retinal plexi, compared with HCs, as previously described.<sup>10</sup>

According to CV risk evaluation, SLE presented higher TG levels, higher TyG Index and higher Framingham and ACC/AHA Risk Scores compared with HCs, all results consistent with current literature.<sup>1 27 28</sup> TG levels have been associated with inflammation and kidney involvement in SLE.<sup>27</sup> TyG Index is a recognised marker of insulin resistance, but recent studies have underlined its role as a possible predictor of CV events in the general population, independently from other traditional CV risk factors.<sup>21 29</sup> There are consistent data showing the relationship between TyG Index with increased carotid IMT, high coronary calcium score and arterial stiffness.<sup>30</sup> In this study, we evaluated for the first time TyG Index as a marker of CV risk in patients with SLE compared with



HCs, though its role needs further validation both in patients with SLE and healthy subjects.

Multivariate sex-adjusted and age-adjusted analyses demonstrated that QRISK3 and IMT are independent risk factors for retinal vascular impairment in SLE. Multivariate analysis did not confirm a relationship between single CV risk factors and retinal vascularisation, but the composite evaluation of some of these factors through the QRISK3 Score was significantly associated with microvascular impairment. This probably reflects the complexity of microvascular damage pathogenesis in patients with SLE, which does not depend by the presence of single CV risk factors, but it is the result of their combination and interaction.

The presence of SLE retinopathy was also assessed, showing a lower prevalence compared with previous findings,<sup>8</sup> probably due to the composition of our population, comprising patients with a lower prevalence of lupus nephritis, younger age and shorter disease duration. Therefore, we did not correlate its presence with OCTA findings and CV risk parameters, but studies with a larger sample size are needed to explore the relationship between established lupus retinopathy and CV involvement.

OCT parameters evaluating retinal layers showed a significant reduction among total retina and GCL segments' thickness in SLE compared with HC. However, no correlations were found between total retina, GCL and RNFL retinal segments and both IMT and QRISK3 Score in SLE.

Retinal thickness in SLE was evaluated in a previous study and it didn't show any significant reduction compared with HCs.<sup>16</sup> These contrasting results suggest that retinal vascular density could be more sensitive in evaluating preclinical retinal alterations in SLE compared to retinal thickness.

We also evaluated presence of RIPLs, retinal alterations that were correlated with established CV disease and that were found to be more prevalent in patients with higher 10-year CV risk.<sup>17 31</sup> Although we didn't identify RIPLs in our population, probably due to the study design, which excluded patients at higher risk to have an established CV disease, these alterations should be evaluated in future studies, considering their relationship with coexisting CV conditions.

A link between subclinical atherosclerosis and retinal vascularisation has been identified both in the general population and in systemic diseases, such as diabetes and hypertension, showing a correlation between reduction of retinal vessel density and increased IMT.<sup>11 12 32</sup> These results highlight a relationship between microcirculation and macrocirculation, probably related to common pathogenetic mechanisms. In SLE, accelerated atherosclerosis and retinal vascular involvement could share a similar pathophysiology, characterised by a systemic inflammatory process involving the endothelium.<sup>4 33</sup>

In our study, IMT values were similar between patients and controls. We can speculate that this lack of difference

depends on the relatively short duration of SLE, young age, small sample size and absence of well-known CV risk factors such as diabetes, hypertension and obesity. Limitations of this study are the small sample size, the cross-sectional design and the lack of evaluation of ongoing antirheumatic treatments.

Further studies are necessary with a longer observational period and a prospective design, in order to confirm the link between ocular vascular impairment and subclinical atherosclerosis. The impact of different immunosuppressive treatments on these conditions should also be assessed.

## CONCLUSIONS

Patients with SLE showed a reduction in retinal microvascularisation compared with HCs, together with higher CV risk indicators, such as TG levels, TyG Inde, Framingham and ACC/AHA risk scores. Among the SLE cohort, QRISK3 Score and IMT showed to be independent risk factors for subclinical retinal vascular impairment.

In conclusion, these results suggest that retinal vessel density detected through OCTA could represent an instrument to evaluate CV involvement in SLE at its preclinical stage.

**Contributors** SF, PC, SR, AB, RM, CNu, MF, MSC and MC contributed to the study conception and design. SF, PC, SR, SL, CNe, FC and MSC contributed to the acquisition of data. SF, PC, SR and MC contributed to the data analysis and interpretation. MC is responsible for the overall content as the guarantor. All authors were involved in drafting the article or revising it critically for important intellectual content and approved the final version to be published. All authors agreed to be accountable for all aspects of the work.

**Funding** The authors have not declared a specific grant for this research from any funding agency in the public, commercial or not-for-profit sectors.

**Competing interests** None declared.

**Patient and public involvement statement** Patients and/or the public were not involved in the design, or conduct, or reporting, or dissemination plans of this research.

**Patient consent for publication** Not applicable.

**Ethics approval** This study involves human participants and was approved by the Ethics Committee of the University Hospital Policlinic of Rome Tor Vergata (RS 253.22), Italy. Participants gave written informed consent to participate in the study before taking part according to the Declaration of Helsinki (updated 2008).

**Provenance and peer review** Not commissioned; externally peer reviewed.

**Data availability statement** Data are available upon reasonable request.

**Supplemental material** This content has been supplied by the author(s). It has not been vetted by BMJ Publishing Group Limited (BMJ) and may not have been peer-reviewed. Any opinions or recommendations discussed are solely those of the author(s) and are not endorsed by BMJ. BMJ disclaims all liability and responsibility arising from any reliance placed on the content. Where the content includes any translated material, BMJ does not warrant the accuracy and reliability of the translations (including but not limited to local regulations, clinical guidelines, terminology, drug names and drug dosages), and is not responsible for any error and/or omissions arising from translation and adaptation or otherwise.

**Open access** This is an open access article distributed in accordance with the Creative Commons Attribution Non Commercial (CC BY-NC 4.0) license, which permits others to distribute, remix, adapt, build upon this work non-commercially, and license their derivative works on different terms, provided the original work is properly cited, appropriate credit is given, any changes made indicated, and the use is non-commercial. See: <http://creativecommons.org/licenses/by-nc/4.0/>.

## ORCID iD

Sara Ferrigno <http://orcid.org/0000-0003-4076-3734>

## REFERENCES

- 1 Giannelou M, Mavragani CP. Cardiovascular disease in systemic lupus erythematosus: a comprehensive update. *J Autoimmun* 2017;82:1–12.
- 2 Esdaile JM, Abrahamowicz M, Grodzicky T, et al. Traditional Framingham risk factors fail to fully account for accelerated atherosclerosis in systemic lupus erythematosus. *Arthritis Rheum* 2001;44:2331–7.
- 3 Di Battista M, Tani C, Elefante E, et al. Framingham, ACC/AHA or QRISK3: which is the best in systemic lupus erythematosus cardiovascular risk estimation? *Clin Exp Rheumatol* 2020;38:602–8.
- 4 Ding X, Xiang W, He X. IFN-I mediates dysfunction of endothelial progenitor cells in atherosclerosis of systemic lupus erythematosus. *Front Immunol* 2020;11:581385.
- 5 Svensson C, Eriksson P, Zachrisson H, et al. High-frequency ultrasound of multiple arterial areas reveals increased intima media thickness, vessel wall appearance, and atherosclerotic plaques in systemic lupus erythematosus. *Front Med (Lausanne)* 2020;7:581336.
- 6 Lertratanakul A, Sun J, Wu PW, et al. Risk factors for changes in carotid intima media thickness and plaque over 5 years in women with systemic lupus erythematosus. *Lupus Sci Med* 2021;8:e000548.
- 7 Seth G, Chengappa KG, Misra DP, et al. Lupus retinopathy: a marker of active systemic lupus erythematosus. *Rheumatol Int* 2018;38:1495–501.
- 8 Conigliaro P, Giannini C, Ferrigno S, et al. Assessment of microvascular involvement in lupus nephritis patients by retinal OCT-angiography and kidney biopsies. *Clin Exp Rheumatol* 2023;41:581–8.
- 9 Monteiro-Henriques I, Rocha-Sousa A, Barbosa-Breda J. Optical coherence tomography angiography changes in cardiovascular systemic diseases and risk factors: a review. *Acta Ophthalmol* 2022;100:e1–15.
- 10 Conigliaro P, Cesareo M, Chimenti MS, et al. Evaluation of retinal microvascular density in patients affected by systemic lupus erythematosus: an optical coherence tomography angiography study. *Ann Rheum Dis* 2019;78:287–9.
- 11 Yoon J, Kang HJ, Lee JY, et al. Associations between the macular microvasculatures and subclinical atherosclerosis in patients with type 2 diabetes: an optical coherence tomography angiography study. *Front Med (Lausanne)* 2022;9:843176.
- 12 Rogowska A, Obrycki Ł, Kutaga Z, et al. Remodeling of retinal microcirculation is associated with Subclinical arterial injury in hypertensive children. *Hypertension* 2021;77:1203–11.
- 13 Aringer M, Costenbader K, Daikh D, et al. European League Against Rheumatism/American College of Rheumatology classification criteria for systemic lupus erythematosus. *Arthritis Rheumatol* 2019;71:1400–12.
- 14 Marmor MF, Kellner U, Lai TYY, et al. Recommendations on screening for chloroquine and hydroxychloroquine retinopathy (2016 revision). *Ophthalmology* 2016;123:1386–94.
- 15 Kharel Sitaula R, Shah DN, Singh D. Role of lupus retinopathy in systemic lupus erythematosus. *J Ophthalmic Inflamm Infect* 2016;6:15.
- 16 Conigliaro P, Triggianese P, Draghessi G, et al. Evidence for the detection of subclinical retinal involvement in systemic lupus erythematosus and Sjögren syndrome: a potential association with therapies. *Int Arch Allergy Immunol* 2018;177:45–56.
- 17 Long CP, Chan AX, Bakhom CY, et al. Prevalence of subclinical retinal ischemia in patients with cardiovascular disease - a hypothesis driven study. *EClinicalMedicine* 2021;33:100775.
- 18 Cesareo M, Giannini C, Di Marino M, et al. Optical coherence tomography angiography in the multimodal assessment of the retinal posterior pole in autosomal dominant optic atrophy. *Acta Ophthalmol* 2022;100:e798–806.
- 19 Gladman DD, Ibañez D, Urowitz MB. Systemic lupus erythematosus disease activity index 2000. *J Rheumatol* 2002;29:288–91.
- 20 Gladman D, Ginzler E, Goldsmith C, et al. The development and initial validation of the systemic lupus International collaborating clinics/American College of Rheumatology damage index for systemic lupus erythematosus. *Arthritis Rheum* 1996;39:363–9.
- 21 Cho DS, Woo S, Kim S, et al. Estimation of plasma apolipoprotein B concentration using routinely measured lipid biochemical tests in apparently healthy Asian adults. *Cardiovasc Diabetol* 2012;11:55.
- 22 Lopez-Jaramillo P, Gomez-Arbelaiz D, Martinez-Bello D, et al. Association of the triglyceride glucose index as a measure of insulin resistance with mortality and cardiovascular disease in populations from five continents (PURE study): a prospective cohort study. *Lancet Healthy Longev* 2023;4:e23–33.
- 23 Mahmood SS, Levy D, Vasan RS, et al. The Framingham heart study and the epidemiology of cardiovascular disease: a historical perspective. *Lancet* 2014;383:999–1008.
- 24 Muntner P, Colantonio LD, Cushman M, et al. Validation of the atherosclerotic cardiovascular disease pooled cohort risk equations. *JAMA* 2014;311:1406–15.
- 25 Rizza S, Longo S, Piciocchi G, et al. Carotid intimal medial thickness in rotating night shift is related to I1B/I16 axis. *Nutr Metab Cardiovasc Dis* 2020;30:1826–32.
- 26 Rizza S, Tesaro M, Cardellini M, et al. Insulin resistance and increased intimal medial thickness in glucose tolerant offspring of type 2 diabetic subjects carrying the D298D genotype of endothelial nitric oxide synthase. *Arterioscler Thromb Vasc Biol* 2006;26:431–2.
- 27 Contreras-Haro B, Hernandez-Gonzalez SO, Gonzalez-Lopez L, et al. Fasting triglycerides and glucose index: a useful screening test for assessing insulin resistance in patients diagnosed with rheumatoid arthritis and systemic lupus erythematosus. *Diabetol Metab Syndr* 2019;11:95.
- 28 Huang S, Zhang Z, Cui Y, et al. Dyslipidemia is associated with inflammation and organ involvement in systemic lupus erythematosus. *Clin Rheumatol* 2023;42:1565–72.
- 29 Liu Q, Si F, Liu Z, et al. Association between triglyceride-glucose index and risk of cardiovascular disease among postmenopausal women. *Cardiovasc Diabetol* 2023;22:21.
- 30 Tao LC, Xu JN, Wang TT, et al. Triglyceride-glucose index as a marker in cardiovascular diseases: landscape and limitations. *Cardiovasc Diabetol* 2022;21:68.
- 31 Madala S, Adabifrouzjaei F, Lando L, et al. Ripls, an optical coherence tomography marker of occult cardiovascular disease. *Invest Ophthalmol Vis Sci* 2022;63:1755–F0215.
- 32 Xu Q, Sun H, Yi Q. Association between retinal microvascular metrics using optical coherence tomography angiography and carotid artery stenosis in a Chinese cohort. *Front Physiol* 2022;13:824646.
- 33 Hysa E, Cutolo CA, Gotelli E, et al. Ocular microvascular damage in autoimmune rheumatic diseases: the pathophysiological role of the immune system. *Autoimmun Rev* 2021;20:102796.