






Dancing with disorder: chorea – an unusual and neglected manifestation of antiphospholipid syndrome

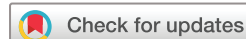Shikai Hu ^{1,2}, Yangzhong Zhou ^{1,3}, Mengtao Li ^{1,3}, Xiaofeng Zeng ^{1,3}, Jiuliang Zhao ^{1,3}

To cite: Hu S, Zhou Y, Li M, *et al.* Dancing with disorder: chorea – an unusual and neglected manifestation of antiphospholipid syndrome. *Lupus Science & Medicine* 2024;**11**:e001332. doi:10.1136/lupus-2024-001332

► Additional supplemental material is published online only. To view, please visit the journal online (<https://doi.org/10.1136/lupus-2024-001332>).

SH and YZ are joint first authors.

Received 31 July 2024
Accepted 17 September 2024



© Author(s) (or their employer(s)) 2024. Re-use permitted under CC BY-NC. No commercial re-use. See rights and permissions. Published by BMJ.

¹Department of Rheumatology and Clinical Immunology, Chinese Academy of Medical Sciences & Peking Union Medical College, Beijing, China

²School of Medicine, Tsinghua Medicine, Tsinghua University, Beijing, China

³National Clinical Research Center for Dermatologic and Immunologic Diseases (NCRC-DID), Ministry of Science and Technology of the People's Republic of China, Beijing, China

Correspondence to

Dr Jiuliang Zhao; zjlpmc@sina.com

ABSTRACT

Objectives Chorea, characterised by involuntary, irregular movements, is a rare neurological manifestation of antiphospholipid syndrome (APS). The specific clinical features remain unclear. This study aimed to summarise the available evidence on antiphospholipid antibody (aPL)-associated chorea.

Methods We used a mixed-methods approach, combining data from patients with chorea with aPL positivity admitted to Peking Union Medical College Hospital (PUMCH) from 2014 to 2024, with cases identified in public databases since 1983. We collected and analysed clinical, laboratory, and imaging results, along with their treatments and outcomes.

Results A total of 180 patients with incident aPL-associated chorea were included (13 from PUMCH and 167 from the literature). The majority (81.7%) were female, with a mean age of chorea onset 22.8 years (SD=16.0). Chorea was the initial symptom in 87.9% of cases and often occurred as a single episode (67%), involving bilateral limbs (58.8%) and both upper and lower limbs (87.2%). 43.3% met the 2023 American College of Rheumatology (ACR)/European Alliance of Associations for Rheumatology (EULAR) APS classification criteria. Thrombocytopenia (30.0%) and arterial thrombosis (29.1%) were the most common manifestations. Lupus anticoagulant was positive in 84.2% of patients, anticardiolipin IgG in 70.8%, and anti-β₂ glycoprotein I IgG in 52.9%. Among those who had results available for the three tests, 57.6% were triple-positive. ANAs were positive in 63.6%. MRI revealed basal ganglia lesions in only 14.8% of patients, whereas all positron emission tomography (PET) scans showed contralateral striatal hypermetabolism. Treatment varied, with most receiving combination therapies of neuroleptics, anticoagulants, antiplatelets, steroids and immunosuppressants. Chorea completely or partially improved in 95.5% of patients.

Conclusion Chorea is a significant but under-recognised manifestation of APS, predominantly affecting young women and often presenting as the initial symptom. Characteristic PET findings of contralateral striatal hypermetabolism can assist in diagnosis. Treatments with glucocorticoids and immunosuppressive therapies appear beneficial. Further research is needed to understand the pathophysiology and optimise management strategies for aPL-associated chorea.

WHAT IS ALREADY KNOWN ON THIS TOPIC

- ⇒ Chorea is a rare but recognised neurological manifestation of antiphospholipid syndrome (APS).
- ⇒ The specific features of antiphospholipid antibody (aPL)-associated chorea, however, remain unclear.

WHAT THIS STUDY ADDS

- ⇒ This study provides a comprehensive data set of the available evidence on aPL-associated chorea, encompassing its clinical, laboratory and radiological features, as well as treatments and outcomes.

HOW THIS STUDY MIGHT AFFECT RESEARCH, PRACTICE OR POLICY

- ⇒ Research: This study underscores the necessity for larger, multicentre studies to validate these findings and explore the biological underpinnings of chorea in APS.
- ⇒ Practice: Clinicians, especially neurologists, should consider aPL-associated chorea in the differential diagnosis of unexplained chorea, particularly in young women.

INTRODUCTION

Antiphospholipid syndrome (APS) is a systemic autoimmune disease characterised by arterial, venous or microvascular thrombosis, and recurrent pregnancy morbidity, associated with persistent antiphospholipid antibodies (aPL). According to the 2006 APS classification criteria, a diagnosis requires at least one clinical criterion (thrombosis or pregnancy morbidity) and one laboratory criterion (persistently positive lupus anticoagulant (LAC), anticardiolipin antibodies (aCL), and/or anti-β₂ glycoprotein I (aβ₂GPI)).¹ However, aPLs are also linked to various clinical manifestations beyond these criteria, including neurological syndromes such as migraine, epilepsy, cognitive dysfunction, and notably, chorea.

Chorea is a movement disorder characterised by irregular, random, involuntary and

jerky movements affecting any part of the body.² The association between chorea and the presence of LAC was first described in 1983 by Dr Graham Hughes in the initial description of APS.³ The Euro-Phospholipid Study, involving a cohort of 1000 patients with APS, reported a 1.3% prevalence of chorea among these individuals.⁴ Despite the 2023 American College of Rheumatology (ACR)/European Alliance of Associations for Rheumatology (EULAR) APS classification criteria introducing some non-criteria manifestations such as thrombocytopenia, microvascular diseases and valvulopathy,⁵ chorea was not included due to its relative rarity and the limited understanding of its clinical features and underlying pathophysiological mechanisms.

Current evidence on aPL-associated chorea is limited to narrative reviews,⁶ case reports and small case series,^{7–10} illustrating highly variable clinical characteristics and outcomes. This variability complicates its diagnosis and treatments. In this study, we aimed to summarise the available evidence on aPL-associated chorea. We employed a mixed-methods approach, combining an incident cohort of aPL-associated chorea from Peking Union Medical College Hospital (PUMCH) with case reports and series from the literature. Our goal was to elucidate the clinical, laboratory and radiological findings, as well as treatments and outcomes of aPL-associated chorea, thereby improving the recognition and diagnosis of chorea in patients with APS.

METHODS

Study population

This study employed a mixed-methods approach, conducting a retrospective, single-arm cohort study of patients with aPL-associated chorea at PUMCH from March 2014 to March 2024. Additionally, we included patients with chorea and aPL positivity with detailed information available in public databases. We conducted a comprehensive search on PubMed (MEDLINE) and EMBASE until March 2024. The search strategy in PubMed was: ((antiphospholipid syndrome) OR (antiphospholipid antibody) OR (lupus anticoagulant) OR (anticardiolipin antibody) OR (anti- β 2-glycoprotein 1 antibody) OR (anti-B2GPI)) AND chorea. We also reviewed references of eligible studies and available reviews.

Patients with confirmed aPL positivity and well-documented episodes of chorea were included. aPL positivity was defined as the presence of any of the following: LAC, aCL IgG/IgM or a β 2GPI IgG/IgM. For patients admitted to PUMCH, LAC was assessed using dilute Russell viper venom time and activated partial thromboplastin time, in accordance with the International Society on Thrombosis and Haemostasis guidelines.¹¹ A patient was considered positive for LAC if the ratio was ≥ 1.2 . Serum aCL and a β 2GPI levels were measured using ELISA, with cut-off values set per the manufacturer's guidelines: moderate-level or high-level aCL and a β 2GPI positivity was defined as a titre ≥ 40 units/mL. For patients

identified from the literature, aPL status was extracted as reported by the authors, whether positive, negative or within the provided range. If this information was unavailable, it was recorded as not reported. Exclusion criteria were articles lacking sufficient detailed data or where chorea was explained by other conditions, inappropriate paper types, non-English or non-Chinese papers, non-human studies, duplicated reports. Two reviewers (SK-H and YZ-Z) independently screened all titles and abstracts for eligibility. Potentially eligible studies were selected for full-text review, with disagreements resolved by reviewing the full text.

Data collection and follow-up

For patients admitted to PUMCH, data were extracted from the hospital electronic medical record system. For patients from the literature, data were collected from the original text and supplementary materials, reported according to the Preferred Reporting Items for Systematic Reviews and Meta-Analyses guidelines.¹² Each case report was considered individually, and for case series or studies including multiple cases, each eligible case was captured separately. If only summarised data were available, we imputed the data for individual cases based on the available information.

We collected demographic information (sex, age of onset of chorea, age of first aPL positivity, diagnosis of SLE, diagnosis of APS), comorbidities, clinical domains, and criteria from the 2023 APS criteria (macrovascular, microvascular, obstetric, cardiac valve, haematology), and aPL positivity information. Additional data included chorea features, laboratory tests (ie, white cell count, red blood cell count, platelet count, C reactive protein (CRP), ANA, antidouble-strand DNA (anti-dsDNA), Coombs' test), cerebrospinal fluid (CSF) results, radiological findings (cerebral MRI, positron emission tomography (PET)-CT, PET-MRI), treatments and outcomes. Patients from the PUMCH cohort were followed until death, lost to follow-up, or March 2024, whichever occurred first.

Statistical analysis

The analysis included measures such as mean, median, SD, range, and quartiles for continuous variables and frequency tables for categorical variables. The distribution of the data was assessed using normality tests, and appropriate descriptive statistics methods were applied to both normally and non-normally distributed variables. For comparison between groups of categorical data, we used Fisher's exact test for expected frequencies of < 5 , otherwise, we used the χ^2 test. R software V.4.2.2 was used to perform statistical analysis.

RESULTS

Patient characteristics

This study included 13 patients from PUMCH and 167 from the literature, totalling 180 patients with aPL-associated chorea.^{7–10 13–98} The flow diagram provided details about the types of studies and the number of cases

included in the analysis (online supplemental figure S1). The demographic and clinical characteristics are summarised in [table 1](#). The median follow-up duration was 22.8 months (range 0.2–588).

In total, 81.7% (147/180) of the patients were female. Remarkably, chorea was the initial symptom in 87.9% (87/99) of patients. The mean age of chorea onset was 22.8 years (SD=16.0) and the mean age of first aPL positivity was 26.1 years (SD=18.2). Among the patients, 43.9% (79/180) had a diagnosis of SLE. Only 41.1% (74/180) met the 2006 Sydney APS classification criteria, while 43.3% (78/180) met the 2023 ACR/EULAR APS classification criteria. Of those meeting the 2023 APS criteria, 52.6% (41/78) were classified as primary APS, and 47.4% (37/78) were secondary to SLE. Comorbidities were unremarkable in PUMCH patients, and data were not available for patients from the literature.

Clinical features and laboratory findings

The most common criteria manifestations were thrombocytopenia (30.0%; 54/180), and arterial thrombosis (29.1%; 52/179) without a high-risk cardiovascular disease profile. Venous thromboembolism was observed in 18.4% (33/179) of patients. The majority of patients (67.0%; 120/179) experienced only one episode of chorea ([table 2](#)). Bilateral chorea was observed in 58.8% (94/160) of patients, while 87.2% (102/117) had involvement of both upper and lower limbs. Isolated lower limb involvement was not seen. Head or face involvement was present in 72.8% (83/114) of patients. Although most patients lacked clear triggers, some had definite precipitating factors, with 7.8% (14/179) associated with oral contraceptives and 7.3% (13/179) associated with pregnancy. The duration of the chorea varied widely, from days to years. While some patients recovered within days (1.2%; 2/166), the majority required months (58.4%; 97/166) or even years (22.3%; 37/166) for improvement.

Laboratory findings indicated lymphopenia, anaemia and abnormal kidney function, including elevated serum creatinine, proteinuria and haematuria, although these abnormalities were infrequent. Elevated CRP levels were noted in 14.3% (4/28) of patients. Among the 38 patients with CSF data, none had abnormal CSF cell counts and biochemistry, suggesting no obvious inflammation in CSF in aPL-associated chorea.

Regarding aPL, LAC was positive in 84.2% (144/171) of patients, aCL IgG in 70.8% (121/171) and aCL IgM in 31.6% (54/171). a β 2GPI IgG was positive in 52.9% (36/68) of patients, and a β 2GPI IgM in 19.1% (13/68). Among those who had results available for the three tests, 57.6% (38/66) were triple-positive (LAC + aCL IgG or IgM + a β 2GPI IgG or IgM). Additionally, ANAs were positive in 63.6% (91/143) of patients, anti-dsDNA in 35.4% (45/127), and the Coombs' test was positive in 32.7% (17/52).

Radiological features

Cerebral MRI scans revealed abnormalities in nearly half of the patients (48.1%; 65/135) ([table 2](#)). Among them, the most common abnormalities were white matter hyperintensities, observed in 61.2% (30/49) of patients with MRI abnormalities. These lesions typically appeared as scattered punctate and patchy foci in white matter, presenting as hypointensities on T1-weighted images and hyperintensities on T2-weighted images and fluid attenuated inversion recovery (FLAIR) sequences. Basal ganglia lesions appeared in only 14.8% (20/135) of all patients with available MRI data and accounted for 30.8% (20/65) of those with MRI abnormalities.

Less than 10% of patients underwent brain metabolic imaging, mostly using PET-CT, and in some cases, PET-MRI. We identified 5 patients from PUMCH and 11 patients from the literature ([table 3](#)). Intriguingly, all the patients (100%; 16/16) exhibited hypermetabolism in the basal ganglia, predominantly on the side contralateral to the abnormal movements. Among them, 15 had no lesions in the basal ganglia on MRI, while one had a small area of substance loss due to old haemorrhages. Contralateral striatal hypermetabolism was a functional concomitant of chorea, with elevated metabolism observed during chorea episodes and returning to normal once the chorea subsided ([figure 1](#)). Additionally, a third of the patients (37.5%; 6/16) also exhibited hypometabolism in other brain regions, though the clinical significance of this finding remains unclear.

Treatments and outcomes

Treatments for aPL-associated chorea were heterogeneous ([table 4](#)). Some cases resolved spontaneously or on discontinuation of triggers, while others required symptomatic treatments, anticoagulation (AC) and antiplatelet (AP) therapies, glucocorticoids (GC), and immunosuppressive therapies (ISTs). GC was the most frequently used treatment, employed in 61.2% (101/165) of cases. Among these, 49.5% (50/101) were treated with oral prednisone, and 27.7% (28/101) received pulses of methylprednisolone. Symptomatic control drugs were the next most common therapies, used in 53.9% (89/165) of cases, including medications such as haloperidol or clonazepam. AC was used in 28.5% (47/165) and AP in 40.0% (66/165) of patients. The top three ISTs were cyclophosphamide, mycophenolate mofetil and azathioprine.

Outcomes were generally favourable ([table 4](#)). Chorea completely resolved in 74.8% (101/135) of patients and partially improved in 20.7% (28/135). Only a few cases remained unchanged or worsened. The addition of GC and/or IST to AC and/or AP therapies was associated with a higher complete resolution rate (61.5% with GC/IST vs 48.6% without GC/IST), supporting the use of GC/IST in treating aPL-associated chorea.

DISCUSSION

In this mixed-methods study, we conducted a comprehensive characterisation of the clinical presentation of

Table 1 Demographic and clinical characteristics of patients with antiphospholipid antibody-associated chorea

	PUMCH (n=13)	Literature (n=167)	Overall (n=180)
Demographics			
Sex, female	8/13 (61.5)	139/167 (83.2)	147/180 (81.7)
Age of onset of chorea, years	25.0±15.9	22.6±16.0	22.8±16.0
Age of first aPL positivity, years	25.1±16.0	26.3±18.6	26.1±18.2
Time from first aPL positivity to onset of chorea, months	-1.2 (-14.1, 11.3)	0 (-60.0, 336.0)	0 (-60.0, 336.0)
Chorea as initial presentations	10/12 (83.3)	77/87 (88.5)	87/99 (87.9)
SLE criteria met	8/13 (61.5)	71/167 (42.5)	79/180 (43.9)
2006 APS criteria met	5/13 (38.5)	69/167 (41.3)	74/180 (41.1)
2023 APS criteria met	6/13 (46.2)	72/167 (43.1)	78/180 (43.3)
PAPS	2/6 (33.3)	39/72 (54.2)	41/78 (52.6)
SAPS (secondary to SLE)	4/6 (66.7)	33/72 (45.8)	37/78 (47.4)
Comorbidities			
Smoking	0/11 (0)	-	-
Obesity (BMI ≥30 kg/m ²)	0/11 (0)	-	-
Arterial hypertension	2/11 (18.2)	-	-
Diabetes mellitus	0/11 (0)	-	-
Coronary artery disease	0/11 (0)	-	-
Hyperlipidaemia	2/11 (18.2)	-	-
Hyperhomocysteinemia	2/11 (18.2)	-	-
Clinical features			
VTE with a high-risk VTE profile	0/12 (0)	0/167 (0)	0/179 (0)
VTE without a high-risk VTE profile	1/12 (8.3)	32/167 (19.3)	33/179 (18.4)
AT with a high-risk CVD profile	0/12 (0)	2/167 (1.2)	2/179 (1.1)
AT without a high-risk CVD profile	4/12 (33.3)	48/167 (28.7)	52/179 (29.1)
Suspected livedo racemosa	0/12 (0)	11/167 (6.6)	11/179 (6.1)
Suspected livedoid vasculopathy lesions	0/12 (0)	0/167 (0)	0/179 (0)
Suspected acute/chronic aPL nephropathy	2/12 (16.7)	0/167 (0)	2/179 (1.1)
Suspected pulmonary haemorrhage	1/12 (8.3)	0/167 (0)	1/179 (0.6)
Established livedoid vasculopathy	0/12 (0)	1/167 (0.6)	1/179 (0.6)
Established acute/chronic aPL nephropathy	0/12 (0)	2/167 (1.2)	2/179 (1.1)
Established pulmonary haemorrhage	0/12 (0)	0/167 (0)	0/179 (0)
Established myocardial disease	0/12 (0)	0/167 (0)	0/179 (0)
Established adrenal haemorrhage	0/12 (0)	0/167 (0)	0/179 (0)
Obstetric events	1/8 (12.5)	22/114 (19.3)	23/122 (18.9)
Cardiac valve thickening	0/12 (0)	6/138 (4.3)	6/150 (4.0)
Cardiac valve vegetation	1/12 (8.3)	7/138 (5.1)	8/150 (5.3)
Thrombocytopenia	4/13 (30.8)	50/167 (29.9)	54/180 (30.0)
Laboratory features			
Lymphopenia	0/13 (0)	14/114 (12.3)	14/127 (11.0)
Anaemia	2/13 (15.4)	21/114 (18.4)	23/127 (18.1)
Thrombocytopenia during chorea	3/13 (23.1)	41/114 (36.0)	44/127 (34.6)
High serum creatinine	2/13 (15.4)	6/46 (13.0)	8/59 (13.6)
Proteinuria	5/13 (38.5)	13/51 (25.5)	18/64 (28.1)
Haematuria	3/13 (23.1)	5/44 (11.4)	8/57 (14.0)

Continued

Table 1 Continued

	PUMCH (n=13)	Literature (n=167)	Overall (n=180)
High hsCRP	1/10 (10)	3/18 (16.7)	4/28 (14.3)
CSF availability	8/13 (61.5)	30/167 (18.0)	38/180 (21.1)
CSF abnormality	0/8 (0)	0/30 (0)	0/38 (0)
Appearance, clear	8/8 (100)	–	–
Pressure, mm H ₂ O	133.4±29.7	–	–
CSF white cell count, × 10 ⁶ /L	0.8±0.97	–	–
CSF-Glu, mmol/L	3.3±0.5	–	–
CSF-Cl, mmol/L	125.1±1.9	–	–
CSF-Pro, g/L	0.4±0.2	–	–
CSF-IgG, mg/L	22.9±9.1	–	–
CSF-OB, Neg	4/8 (50)	–	–
CSF-SOB, Neg	4/8 (50)	–	–
LAC	13/13 (100)	131/158 (82.9)	144/171 (84.2)
aCL	11/13 (84.6)	135/158 (85.4)	146/171 (85.4)
aCL IgM	1/11 (9.1)	53/135 (39.3)	54/146 (37.0)
aCL IgG	10/11 (90.9)	111/135 (82.2)	121/146 (82.9)
aβ2GPI	11/13 (84.6)	31/55 (56.4)	42/68 (61.8)
aβ2GPI IgM	1/11 (9.1)	12/31 (38.7)	13/42 (31.0)
aβ2GPI IgG	10/11 (90.9)	26/31 (83.9)	36/42 (85.7)
Single aPL positivity	2/13 (15.4)	16/53 (30.2)	18/66 (27.3)
Isolated LAC	2/2 (100.0)	12/16 (75)	14/18 (77.8)
Isolated aCL IgG/M	0/2 (0)	4/16 (25)	4/18 (22.2)
Isolated aβ2GPI IgG/M	0/2 (0)	0/16 (0)	0/18 (0)
Double aPL positivity	0/13 (0)	9/53 (17.0)	9/66 (13.6)
LAC+, aβ2GPI IgG/M–, aCL IgG/M+	0/0 (0)	7/9 (77.8)	7/9 (77.8)
LAC–, aβ2GPI IgG/M+, aCL IgG/M+	0/0 (0)	2/9 (22.2)	2/9 (22.2)
LAC+, aβ2GPI IgG/M+, aCL IgG/M–	0/0 (0)	0/9 (0)	0/9 (0)
Triple aPL positivity	11/13 (84.6)	27/53 (50.9)	38/66 (57.6)
Triple-positive IgG isotype	11/11 (100.0)	23/27 (85.2)	34/38 (89.5)
Triple-positive IgM isotype	1/11 (9.1)	4/27 (14.8)	5/38 (13.2)
ANA	10/13 (76.9)	81/130 (62.3)	91/143 (63.6)
Anti-dsDNA	4/13 (30.8)	41/114 (36.0)	45/127 (35.4)
Coombs' test	7/10 (70.0)	10/42 (23.8)	17/52 (32.7)

Results are shown as n/N (%), mean±SD, or median (range), excluding missing/unknown unless otherwise specified.

aCL, anticardiolipin antibody; aPL, antiphospholipid antibody; APS, antiphospholipid syndrome; AT, arterial thrombosis; aβ2GPI, anti-β2 glycoprotein I antibody; BMI, body mass index; Cl, chloride; CSF, cerebrospinal fluid; CVD, cardiovascular disease; dsDNA, double-strand DNA; Glu, glucose; hsCRP, high-sensitivity C reactive protein; LAC, lupus anticoagulant; Neg, negative; n/N, n instances of positivity out of a total of N instances; OB, oligoclonal bands; PAPS, primary APS; Pro, protein; PUMCH, Peking Union Medical College Hospital; SAPS, secondary APS; SOB, specific oligoclonal bands (oligoclonal bands exit in CSF but not peripheral blood); VTE, venous thromboembolism.

patients with aPL-associated chorea. Our findings provide valuable insights into clinical features, laboratory findings, radiological findings, treatments and outcomes of this rare manifestation. The key findings are: (1) Chorea was the initial symptom in 87.9% of patients, with most first consulting a neurologist. (2) Both the 2006 and 2023 APS classification criteria failed to identify more than half

of the patients. (3) Contralateral striatal hypermetabolism on PET-CT/MRI is highly useful in diagnosing aPL-associated chorea. (4) GCs and ISTs are associated with a higher complete resolution rate.

Chorea can be due to a large number of aetiologies.⁹⁹ While hereditary causes are the most common, identifying acquired or symptomatic chorea is crucial as

Table 2 Clinical presentation and radiological features of antiphospholipid antibody-associated chorea

	PUMCH (n=13)	Literature (n=167)	Overall (n=180)
Episodes			
=1	9/12 (75)	111/167 (66.5)	120/179 (67.0)
>1	3/12 (25)	56/167 (33.5)	59/179 (33.0)
Mean (range)	1.2 (1, 2)	1.5 (1, 6)	1.5 (1, 6)
Localisation			
Unilateral or bilateral			
Bilateral	8/12 (66.7)	86/148 (58.1)	94/160 (58.8)
Unilateral	4/12 (33.3)	62/148 (41.9)	66/160 (37.5)
Upper limb, lower limb, both			
Both	10/12 (83.3)	92/105 (87.6)	102/117 (87.2)
Upper limb	2/12 (16.7)	13/105 (12.4)	15/117 (12.8)
Lower limb	0/12 (0)	0/105 (0)	0/117 (0)
Head or face involvement	9/12 (75)	74/102 (72.5)	83/114 (72.8)
Precipitating factors			
Oral contraceptive	0/12 (0)	14/167 (8.4)	14/179 (7.8)
Pregnancy	1/12 (8.3)	12/167 (7.2)	13/179 (7.3)
None	10/12 (83.3)	139/167 (83.2)	149/179 (83.2)
Duration from onset to improvement			
Days	0/12 (0)	2/154 (1.3)	2/166 (1.2)
Weeks	0/12 (0)	30/154 (19.5)	30/166 (18.1)
Months	12/12 (100)	85/154 (55.2)	97/166 (58.4)
Years	0/12 (0)	37/154 (24.0)	37/166 (22.3)
Duration of follow-up, months			
Median (range)	24.9 (3.1, 97.1)	18 (0.2, 588)	22.8 (0.2, 588)
MRI			
Availability	11/13 (84.6)	124/167 (74.3)	135/180 (75.0)
Abnormality	7/11 (63.6)	58/124 (46.8)	65/135 (48.1)
Basal ganglia lesions	1/7 (14.3)	19/58 (32.8)	20/65 (30.8)
White matter hyperintensities	5/7 (71.4)	25/42 (59.5)	30/49 (61.2)
Atrophy	0/7 (0)	4/42 (9.5)	4/49 (8.2)
PET-CT/MRI			
Availability	5/13 (38.5)	11/167 (6.6)	16/180 (8.9)
Abnormality	5/5 (100.0)	11/11 (100.0)	16/16 (100.0)
Hypermetabolism of basal ganglia	5/5 (100.0)	11/11 (100.0)	16/16 (100.0)
Hypometabolism of other regions	3/5 (60.0)	3/11 (27.3)	6/16 (37.5)
Repeat in complete remission	1/5 (20.0)	5/11 (45.5)	6/16 (37.5)
Back to normal	1/1 (100.0)	5/5 (100.0)	6/6 (100.0)

PET, positron emission tomography; PUMCH, Peking Union Medical College Hospital.

these conditions are potentially treatable. Major causes of acquired chorea include infectious/postinfectious, pharmacological, vascular, metabolic and autoimmune conditions, such as autoimmune encephalitis, SLE and APS.¹⁰⁰ Currently, there are no standard diagnostic criteria for APS-associated chorea. In this study, patients

with a positive aPL test were included. Among them, only 41%–43% met the 2006 or 2023 APS criteria (table 1), significantly lower than the sensitivity reported in patients with general APS.⁵ This lower sensitivity may be due to the rarity of thrombotic events, especially venous thrombosis, and the younger age of many patients with chorea,

Table 3 Summary of brain FDG-PET-CT/MRI results in patients with antiphospholipid antibody-related chorea

Patient	Reference	Age onset	APS	SLE	Chorea localisation	Cerebral FDG-PET results
1	1994-Furie	24	-	-	Uni (alternating)	Contralateral striatal hypermetabolism
2	1998-Sundén-Cullberg	20	-	-	Bi (right>left)	Bilateral striatal hypermetabolism (left>right)
3	2001-Paus	41	-	-	Uni (left)	Contralateral striatal hypermetabolism
4	2004-Léger	20	-	-	Uni (right)	Contralateral striatal hypermetabolism
5	2007-Wu	14	-	-	Bi (alternating)	Contralateral putamen hypermetabolism
6	2010-Demonty	17	-	-	Bi (right=left)	Bilateral striatal hypermetabolism
7	2015-Safarpour	89	-	-	Bi (right>left)	Bilateral striatal hypermetabolism (left>right)
8	2018-Dombernowsky	21	+	-	Bi (unknown)	Bilateral striatal hypermetabolism (right>left)
9	2022-Lerjefors (1)	66	-	-	Bi (right>left)	Bilateral striatal hypermetabolism (right>left) Bilateral parieto-temporal-occipital hypometabolism
10	2022-Lerjefors (2)	55	+	-	Bi (left>right)	Bilateral striatal hypermetabolism (right>left) Left parieto-occipital hypometabolism
11	2023-Farag	33	-	-	Uni (right)	Contralateral striatal hypermetabolism Bilateral temporal hypometabolism
12	This paper 1	24	+	+	Bi (left>right)	Bilateral striatal hypermetabolism (right>left)
13	This paper 2	15	+	+	Bi (left>right)	Bilateral striatal hypermetabolism (right>left) Bilateral frontal-thalamus-cerebellum hypometabolism
14	This paper 3	14	-	+	Bi (right=left)	Bilateral striatal hypermetabolism (right>left) Bilateral cortex hypometabolism
15	This paper 4	21	-	-	Uni (right)	Bilateral striatal hypermetabolism (right putamen, left caudate nucleus) Bilateral parieto-occipital hypometabolism
16	This paper 5	25	-	+	Uni (right)	Contralateral striatal hypermetabolism

APS, antiphospholipid syndrome; Bi, bilateral; FDG-PET, fluorodeoxyglucose positron emission tomography; Uni, unilateral.

precluding pregnancy morbidity. Although both are low, 2023 APS criteria are more sensitive than 2006 criteria in identifying APS-associated chorea. This is because the 2023 ACR/EULAR APS classification criteria introduced some non-criteria manifestations such as thrombocytopenia, microvascular diseases and valvulopathy.⁵

For many years, neuroimaging techniques have focused primarily on structural changes. Our data show that over

half of patients with aPL-associated chorea had normal brain MRI results or non-specific white matter hyperintensities. Only 14.8% (20/135) exhibited basal ganglia lesions (table 2), which were often old and unrelated to the recent chorea, hence not providing additional diagnostic information. Recent advances in functional imaging have enabled the in vivo analysis of neuronal dysfunction and brain activity. PET is a functional imaging technique

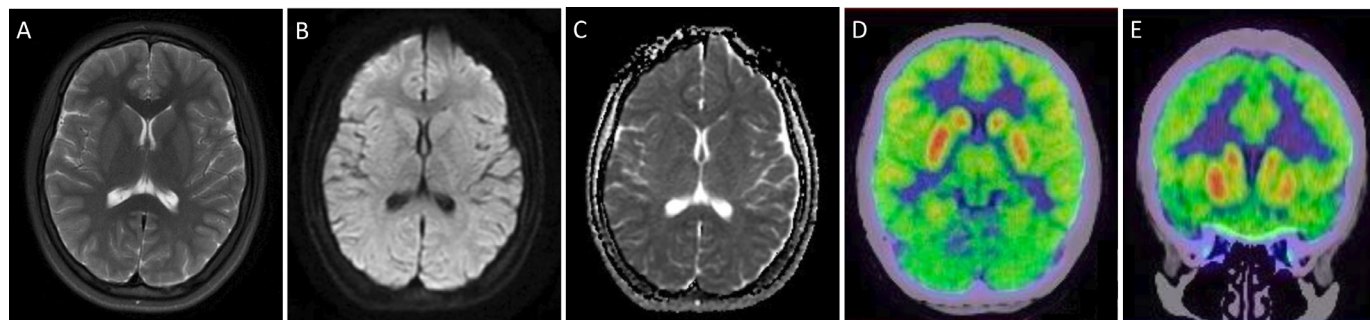


Figure 1 Representative brain MRI and fluorodeoxyglucose positron emission tomography (FDG-PET) images in a patient with antiphospholipid antibody-related chorea. A teenage patient with triple-positive antiphospholipid antibodies presented with bilateral chorea, more dominant on the left side. The brain MRI (A–C) was normal, but FDG-PET-CT (D–E) revealed significant bilateral striatal hypermetabolism, more dominant on the right side.

Table 4 Treatments and outcomes of patients with antiphospholipid antibody-related chorea

	PUMCH (n=13)	Literature (n=167)	Overall (n=180)
Treatments			
Symptomatic treatment	9/12 (75.0)	80/153 (46.1)	89/165 (53.9)
Haloperidol	2/9 (22.2)	31/80 (38.8)	33/89 (37.1)
Tetrabenazine	0/9 (0)	11/80 (13.8)	11/89 (12.4)
Clonazepam	7/9 (77.8)	6/80 (7.5)	13/89 (14.6)
AC	5/12 (41.7)	42/153 (27.5)	47/165 (28.5)
AP	9/12 (75.0)	57/153 (37.3)	66/165 (40.0)
Hydroxychloroquine	12/12 (100.0)	12/153 (7.8)	24/165 (14.5)
GC	11/12 (91.7)	90/153 (58.8)	101/165 (61.2)
Prednisone mono	4/11 (36.4)	46/90 (51.1)	50/101 (49.5)
Pulses of methylprednisolone	7/11 (63.6)	21/90 (23.3)	28/101 (27.7)
IST	11/12 (83.3)	21/153 (13.7)	32/165 (19.4)
Cyclophosphamide	4/11 (36.4)	9/21 (42.9)	13/32 (40.6)
Mycophenolate mofetil	7/11 (63.6)	5/21 (23.8)	12/32 (37.5)
Azathioprine	2/11 (18.2)	9/21 (42.9)	11/32 (34.4)
Tacrolimus	1/11 (9.1)	1/21 (4.8)	2/32 (6.3)
Intravenous immunoglobulin	2/12 (16.7)	11/153 (7.2)	13/165 (7.9)
Plasma exchange	0/12 (0)	2/153 (1.3)	2/165 (1.2)
Rituximab	1/12 (8.3)	3/153 (2.0)	4/165 (2.4)
Belimumab	1/12 (8.3)	1/153 (0.7)	2/165 (1.2)
Outcomes			
Complete resolution	7/12 (58.3)	94/123 (76.4)	101/135 (74.8)
Improved	5/12 (41.7)	23/123 (18.7)	28/135 (20.7)
Worsened	0/12 (0)	2/123 (1.6)	2/135 (1.5)
Unchanged	0/12 (0)	4/123 (3.3)	4/135 (3.0)
Per cent of complete resolution using AC/AP without GC/IST	0/0 (0)	18/37 (48.6)	18/37 (48.6)
Per cent of complete resolution using AC/AP with GC/IST	7/12 (58.3)	33/53 (62.3)	40/65 (61.5)

Results are shown as n/N (%), excluding missing/unknown unless otherwise specified.
AC, anticoagulation; AP, antiplatelet; GC, glucocorticoids; IST, immunosuppressive therapies; PUMCH, Peking Union Medical College Hospital.

that involves the injection of a radiolabelled ligand. This ligand either binds to specific structures, such as neurotransmitter receptors, or integrates into the body's tissues, as with ^{18}F -fluorodeoxyglucose (^{18}F -FDG). ^{18}F -FDG PET imaging provides valuable information in cases of chorea with various aetiologies, offering insights into pathogenesis, disease course and basal ganglia functions. Striatal hypometabolism is associated with neurodegenerative causes of chorea, whereas striatal hypermetabolism tends to be seen in cases of chorea of transient and thus treatable aetiologies, including hyperthyroidism, Sydenham's chorea and aPL-associated chorea.¹⁰¹ We identified 16 patients who had undergone PET-CT/MRI, 5 patients from PUMCH and 11 patients from the literature. Intriguingly, all of them showed contralateral striatal hypermetabolism, while none exhibited abnormalities on MRI (table 3). Moreover, contralateral striatal hypermetabolism is often observed as a functional correlate of chorea, with elevated metabolic activity detected in the striatum during chorea episodes. This heightened metabolism tends to normalise once the chorea subsides, indicating a reversible metabolic alteration associated with the condition (figure 1). This dynamic change underscores the importance of functional imaging in diagnosing and understanding the transient nature of chorea and its underlying pathophysiological mechanisms. Therefore, striatal hypermetabolism is not specific of aPL-associated chorea but one might consider including FDG-PET in the diagnostic workup of patients with chorea of unknown cause.

The pathogenesis of chorea in APS remains unclear, with three main hypotheses proposed.^{6 102} The first involves thrombosis or embolism formation without overt vascular changes. The second suggests autoimmune reactions targeting vascular endothelium, potentially inducing thrombosis formation or non-thrombotic vascular occlusion. The third hypothesis involves autoimmune reactions directly targeting the phospholipid-containing basal ganglia, causing neurotoxicity, loss of neuroplasticity and synaptic transition. Pathogenic autoantibodies may include aPL or unknown antineuron antibodies. In vitro data indicate that aPL can directly permeabilise and depolarise brain synaptoneuroosomes (a composite particle containing one or more presynaptic compartments attached to a postsynaptic element).¹⁰³ However, aPL titres typically remain stable regardless of the clinical course of chorea, prompting the search for new antibodies. Indeed, one study identified serum antistriatal antibodies in two patients, with titres dropping dramatically as chorea improved, while aCL levels remained unchanged during the disease course.⁶² Antineuron antibodies were also identified in patients with movement disorders associated with lupus and aPL by another study.⁷³

Given the heterogeneity in chorea presentation and treatment responses, it is highly plausible that multiple mechanisms, rather than a single one, contribute to these abnormalities. Without biopsy availability, concrete

answers remain elusive. However, one may speculate on the mechanisms based on clinical findings. For patients with bilateral involvement, subacute onset, normal MRI findings and a dramatic response to corticosteroids, autoimmune mechanisms targeting vascular endothelium or basal ganglia neurons likely play a crucial role. Conversely, for patients with unilateral involvement, acute onset, accompanying thrombotic complications (eg, cerebrovascular accidents or deep vein thrombosis), structural MRI abnormalities, and a response to aspirin or anticoagulants, thrombosis formation may be the primary mechanism.

There are no controlled prospective studies on the treatment of aPL-associated chorea. Current treatment regimens are based primarily on open-label studies and expert opinions. Neuroleptics were commonly used for symptomatic control of chorea, usually with good responses. While there have been cases where aspirin and/or anticoagulants led to complete chorea resolution, most patients received combination therapies, including aspirin, anticoagulants, steroids and immunosuppressants. Our analysis of treatment outcomes revealed that patients that received GC and/or IST had a higher complete resolution rate (61.5%) compared with those treated with AC and/or AP therapies alone (48.6%) (table 4). This suggests that for most patients, AC and/or AP alone may not be sufficient to completely eliminate chorea, and the addition of GC and IST may be necessary. Nevertheless, due to the variety of medication combinations used, it is not possible to infer definitive therapeutic guidelines.

Our study has several limitations. As a retrospective study, the data from medical records and particularly from the literature were incomplete, limiting the scope and robustness of further analyses and introducing a risk of reporting bias. The variability in aPL detection methodologies across different studies may account for differences in antibody results between our patients and those reported in the literature. We included only English and Chinese publications, which might result in the exclusion of relevant studies published in other languages, thereby missing potentially important data. Lastly, the literature tends to over-represent unusual, severe or positive outcomes, which could skew the reported clinical features and treatment effects.

CONCLUSION

In conclusion, this study offers a thorough examination of aPL-associated chorea, drawing on the most robust evidence from an incident cohort of 180 patients spanning the past 40 years. Despite its rarity, chorea emerges as a noteworthy manifestation of APS. Our findings underscore the crucial significance of promptly recognising and testing for aPL in cases of unexplained chorea. This awareness is pivotal, as aPL-associated chorea is a treatable condition with a favourable outcome.

Contributors SK-H designed the study, analysed data, interpreted results and wrote the manuscript; YZ-Z analysed data, interpreted results and revised the manuscript; MT-L and XF-Z provided guidance and revised the content; JL-Z provided guidance, checked the data, revised the content and acted as the guarantor of the work.

Funding This study was supported by the Chinese National Key Technology R&D Program, Ministry of Science and Technology (2021YFC2501300), Beijing Municipal Science & Technology Commission (Z201100005520027), CAMS Innovation Fund for Medical Sciences (CIFMS) (2021-I2M-1-005), National High Level Hospital Clinical Research Funding (2022-PUMCH-A-008, A-065, B-013, D-009).

Competing interests None declared.

Patient consent for publication Consent obtained directly from patient(s).

Ethics approval This study involves human participants. The cohort establishment received ethical approval from the Medical Ethics Committee of Peking Union Medical College Hospital (HS-3309). Participants gave informed consent to participate in the study before taking part.

Provenance and peer review Not commissioned; externally peer reviewed.

Data availability statement Data are available upon reasonable request.

Supplemental material This content has been supplied by the author(s). It has not been vetted by BMJ Publishing Group Limited (BMJ) and may not have been peer-reviewed. Any opinions or recommendations discussed are solely those of the author(s) and are not endorsed by BMJ. BMJ disclaims all liability and responsibility arising from any reliance placed on the content. Where the content includes any translated material, BMJ does not warrant the accuracy and reliability of the translations (including but not limited to local regulations, clinical guidelines, terminology, drug names and drug dosages), and is not responsible for any error and/or omissions arising from translation and adaptation or otherwise.

Open access This is an open access article distributed in accordance with the Creative Commons Attribution Non Commercial (CC BY-NC 4.0) license, which permits others to distribute, remix, adapt, build upon this work non-commercially, and license their derivative works on different terms, provided the original work is properly cited, appropriate credit is given, any changes made indicated, and the use is non-commercial. See: <http://creativecommons.org/licenses/by-nc/4.0/>.

ORCID iDs

Shikai Hu <http://orcid.org/0000-0002-0817-991X>

Yangzhong Zhou <http://orcid.org/0000-0003-3497-0075>

Mengtao Li <http://orcid.org/0000-0002-4171-9738>

Xiaofeng Zeng <http://orcid.org/0000-0002-3883-2318>

Jiuliang Zhao <http://orcid.org/0000-0001-9308-2858>

REFERENCES

- Miyakis S, Lockshin MD, Atsumi T, *et al.* International consensus statement on an update of the classification criteria for definite antiphospholipid syndrome (APS). *J Thromb Haemost* 2006;4:295–306.
- Bertsias GK, Ioannidis JPA, Aringer M, *et al.* EULAR recommendations for the management of systemic lupus erythematosus with neuropsychiatric manifestations: report of a task force of the EULAR standing committee for clinical affairs. *Ann Rheum Dis* 2010;69:2074–82.
- Hughes GR. The prosser-white oration. *Clin Exp Dermatol* 1983;9:535–44.
- Cervera R, Piette J-C, Font J, *et al.* Antiphospholipid syndrome: clinical and immunologic manifestations and patterns of disease expression in a cohort of 1,000 patients. *Arthritis Rheum* 2002;46:1019–27.
- Barbhaiya M, Zuily S, Naden R, *et al.* The 2023 ACR/EULAR antiphospholipid syndrome classification criteria. *Arthritis Rheumatol* 2023;75:1687–702.
- Peluso S, Antenora A, De Rosa A, *et al.* Antiphospholipid-related chorea. *Front Neurol* 2012;3:150.
- Asherson RA, Derksen RH, Harris EN, *et al.* Chorea in systemic lupus erythematosus and “lupus-like” disease: association with antiphospholipid antibodies. *Semin Arthritis Rheum* 1987;16:253–9.
- Cervera R, Asherson RA, Font J, *et al.* Chorea in the antiphospholipid syndrome. Clinical, radiologic, and immunologic characteristics of 50 patients from our clinics and the recent literature. *Medicine (Baltimore)* 1997;76:203–12.
- Orzechowski NM, Wolanskyj AP, Ahlskog JE, *et al.* Antiphospholipid antibody-associated chorea. *J Rheumatol* 2008;35:2165–70.
- Reiner P, Galanaud D, Leroux G, *et al.* Long-term outcome of 32 patients with chorea and systemic lupus erythematosus or antiphospholipid antibodies. *Mov Disord* 2011;26:2422–7.
- Devreese KMJ, de Groot PG, de Laat B, *et al.* Guidance from the scientific and standardization committee for lupus anticoagulant/antiphospholipid antibodies of the international society on thrombosis and haemostasis: update of the guidelines for lupus anticoagulant detection and interpretation. *J Thromb Haemost* 2020;18:2828–39.
- Page MJ, McKenzie JE, Bossuyt PM, *et al.* The PRISMA 2020 statement: an updated guideline for reporting systematic reviews. *BMJ* 2021;372:n71:71:.
- Lubbe WF, Walker EB. Chorea gravidarum associated with circulating lupus anticoagulant: successful outcome of pregnancy with prednisone and aspirin therapy. Case report. *Br J Obstet Gynaecol* 1983;90:487–90.
- Bouchez B, Arnott G, Hatron PY, *et al.* Chorea and systemic lupus erythematosus with circulating anticoagulant. 3 cases. *Rev Neurol (Paris)* 1985;141:571–7.
- Asherson RA, Harris NE, Gharavi AE, *et al.* Systemic lupus erythematosus, antiphospholipid antibodies, chorea, and oral contraceptives. *Arthritis Rheum* 1986;29:1535–6.
- Hodges JR. Chorea and the lupus anticoagulant. *J Neurol Neurosurg Psychiatry* 1987;50:368–9.
- Pincemaille O, Jeannoel P, Pouzol P, *et al.* Acute chorea, systemic lupus erythematosus and antiphospholipid antibodies. Apropos of a case. *Pediatric (Bucur)* 1987;42:157–60.
- Asherson RA, Gibson DG, Evans DW, *et al.* Diagnostic and therapeutic problems in two patients with antiphospholipid antibodies, heart valve lesions, and transient ischaemic attacks. *Ann Rheum Dis* 1988;47:947–53.
- Asherson RA, Hughes GR. Antiphospholipid antibodies and chorea. *J Rheumatol* 1988;15:377–9.
- Khamashta MA, Gil A, Anciones B, *et al.* Chorea in systemic lupus erythematosus: association with antiphospholipid antibodies. *Ann Rheum Dis* 1988;47:681–3.
- Mathur AK, Gatter RA. Chorea as the initial presentation of oral contraceptive induced systemic lupus erythematosus. *J Rheumatol* 1988;15:1042–3.
- Okseter K, Sirnes K. Chorea and lupus anticoagulant: a case report. *Acta Neurol Scand* 1988;78:206–9.
- Iskander MK, Khan M. Chorea as the initial presentation of oral contraceptive related systemic lupus erythematosus. *J Rheumatol* 1989;16:850–1.
- Nogawa S, Hirakata M, Kaburaki J, *et al.* A case of anti-phospholipid antibody syndrome presenting chorea as an initial manifestation. *Ryumachi* 1989;29:134–42.
- Rose CD, Goldsmith DP. Childhood adrenal insufficiency, chorea, and antiphospholipid antibodies. *Ann Rheum Dis* 1990;49:421–2.
- Falcini F, Taccetti G, Trapani S, *et al.* Primary antiphospholipid syndrome: a report of two pediatric cases. *J Rheumatol* 1991;18:1085–7.
- Gutrecht JA, Kattwinkel N, Stillman MJ. Retinal migraine, chorea, and retinal artery thrombosis in a patient with primary antiphospholipid antibody syndrome. *J Neurol* 1991;238:55–6.
- Sugiyama Y, Yamamoto T, Tsukamoto T, *et al.* A case of chorea as a sole presentation of primary anti-phospholipid antibody syndrome. *Rinsho Shinkeigaku* 1991;31:1224–8.
- Ucles A, Macías M, Brañas F, *et al.* Chorea and lupus anticoagulant. *Neurologia* 1991;6:266–7.
- Vlachoyiannopoulos PG, Dimou G, Siamopoulou-Mavridou A. Chorea as a manifestation of the antiphospholipid syndrome in childhood. *Clin Exp Rheumatol* 1991;9:303–5.
- Forrett-Kaminsky MC, Scherer C, Kaminsky P, *et al.* Magnetic resonance imaging in lupic chorea. *Rev Neurol (Paris)* 1992;148:383–4.
- Omdal R, Roalsø S. Chorea gravidarum and chorea associated with oral contraceptives--diseases due to antiphospholipid antibodies? *Acta Neurol Scand* 1992;86:219–20.
- Schiff DE, Ortega JA. Chorea, eosinophilia, and lupus anticoagulant associated with acute lymphoblastic leukemia. *Pediatr Neurol* 1992;8:466–8.
- Shimomura T, Takahashi S, Takahashi S. Chorea associated with antiphospholipid antibodies. *Rinsho Shinkeigaku* 1992;32:989–93.
- van Heereveld HA, van den Hoogen FH, de Vaan G, *et al.* Chorea and primary antiphospholipid syndrome. *Ned Tijdschr Geneesk* 1992;136:1917–9.
- Vilches RM, Tamayo JA, Mínguez A, *et al.* Chorea and primary antiphospholipid syndrome: effective treatment. *Neurologia* 1992;7:120.

- 37 Caramelli P, Toledo SM, Marchiori PE, *et al.* Chorea as a sign of systemic lupus erythematosus activity. Case report. *Arq Neuropsiquiatr* 1993;51:267–9.
- 38 Kirk A, Harding SR. Cardioembolic caudate infarction as a cause of hemichorea in lupus anticoagulant syndrome. *Can J Neurol Sci* 1993;20:162–4.
- 39 Besbas N, Damarguc I, Ozen S, *et al.* Association of antiphospholipid antibodies with systemic lupus erythematosus in a child presenting with chorea: a case report. *Eur J Pediatr* 1994;153:891–3.
- 40 Furie R, Ishikawa T, Dhawan V, *et al.* Alternating hemichorea in primary antiphospholipid syndrome: evidence for contralateral striatal hypermetabolism. *Neurology (ECRicon)* 1994;44:2197–9.
- 41 Nomura M, Okada J, Tateno S, *et al.* Renal thrombotic microangiopathy in a patient with rheumatoid arthritis and antiphospholipid syndrome: successful treatment with cyclophosphamide pulse therapy and anticoagulant. *Intern Med* 1994;33:484–7.
- 42 al Jishi F, al Kawi MZ, el Ramahi K, *et al.* Hemichorea in systemic lupus erythematosus: significance of MRI findings. *Lupus (Los Angel)* 1995;4:321–3.
- 43 Al-Zahrani AS, Bohlega SA. Chorea and high antiphospholipid antibodies: probable primary antiphospholipid syndrome. *Eur J Neurol* 1995;2:363–7.
- 44 Steinlin M, Blaser SI, Gilday DL, *et al.* Neurologic manifestations of pediatric systemic lupus erythematosus. *Pediatr Neurol* 1995;13:191–7.
- 45 Tam LS, Cohen MG, Li EK. Hemiballismus in systemic lupus erythematosus: possible association with antiphospholipid antibodies. *Lupus (Los Angel)* 1995;4:67–9.
- 46 Masala C, Morino S, Zangari P, *et al.* Chorea in primary antiphospholipid syndrome. *Clin Neurol Neurosurg* 1996;98:247–8.
- 47 Neau JP, Guilhot F, Boinot C, *et al.* Development of chorea with lupus anticoagulant after interferon therapy. *Eur Neurol* 1996;36:235–6.
- 48 Van Horn G, Arnett FC, Dimachkie MM. Reversible dementia and chorea in a young woman with the lupus anticoagulant. *Neurology (ECRicon)* 1996;46:1599–603.
- 49 de la Fuente-Fernández R. Lupus anticoagulant and chorea. *Neurology (ECRicon)* 1997;49:639–40.
- 50 Fung VS, Yiannikas C, Sue CM, *et al.* Is Sydenham's chorea an antiphospholipid syndrome? *J Clin Neurosci* 1998;5:115–8.
- 51 Sundén-Cullberg J, Tedroff J, Aquilonius SM. Reversible chorea in primary antiphospholipid syndrome. *Mov Disord* 1998;13:147–9.
- 52 Adcock J, Garrick R, Kelly P. A case of thyrotoxicosis with chorea: association with anti-phospholipid antibody. *J Clin Neurosci* 1999;6:168–71.
- 53 Amital H, Langevitz P, Levy Y, *et al.* Valvular deposition of antiphospholipid antibodies in the antiphospholipid syndrome: a clue to the origin of the disease. *Clin Exp Rheumatol* 1999;17:99–102.
- 54 Kiechl-Kohlendorfer U, Ellemunter H, Kiechl S. Chorea as the presenting clinical feature of primary antiphospholipid syndrome in childhood. *Neuropediatrics* 1999;30:96–8.
- 55 Nordal EB, Nielsen J, Marhaug G. Chorea in juvenile primary antiphospholipid syndrome. Reversible decreased circulation in the basal ganglia visualised by single photon emission computed tomography. *Scand J Rheumatol* 1999;28:324–7.
- 56 Harel L, Zecharia A, Straussberg R, *et al.* Successful treatment of rheumatic chorea with carbamazepine. *Pediatr Neurol* 2000;23:147–51.
- 57 Okun MS, Jummani RR, Carney PR. Antiphospholipid-associated recurrent chorea and ballism in a child with cerebral palsy. *Pediatr Neurol* 2000;23:62–3.
- 58 Paus S, Pöttsch B, Risse JH, *et al.* Chorea and antiphospholipid antibodies: treatment with methotrexate. *Neurology (ECRicon)* 2001;56:137–8.
- 59 Ciubotaru CR, Esfahani F, Benedict RHB, *et al.* Chorea and rapidly progressive subcortical dementia in antiphospholipid syndrome. *J Clin Rheumatol* 2002;8:332–9.
- 60 Al-Herz A. Chorea can present long before other manifestations of primary antiphospholipid syndrome. *Ann Saudi Med* 2003;23:89–91.
- 61 Binstadt BA, Caldas AMC, Turvey SE, *et al.* Rituximab therapy for multisystem autoimmune diseases in pediatric patients. *J Pediatr* 2003;143:598–604.
- 62 Léger GC, Johnson N, Horowitz SW, *et al.* Dementia-like presentation of striatal hypermetabolic state with antistriatal antibodies responsive to steroids. *Arch Neurol* 2004;61:754–7.
- 63 Watanabe T, Onda H. Hemichorea with antiphospholipid antibodies in a patient with lupus nephritis. *Pediatr Nephrol* 2004;19:451–3.
- 64 Engelen M, Tijssen MAJ. Paroxysmal non-kinesigenic dyskinesia in antiphospholipid syndrome. *Mov Disord* 2005;20:111–3.
- 65 Mastorodemos V, Mamoulaki M, Kritikos H, *et al.* Central nervous system involvement as the presenting manifestation of autoimmune rheumatic diseases: an observational study using the American College of Rheumatology nomenclature for neuropsychiatric lupus. *Clin Exp Rheumatol* 2006;24:629–35.
- 66 Gidwani P, Segal E, Shanske A, *et al.* Chorea associated with antiphospholipid antibodies in a patient with Kabuki syndrome. *Am J Med Genet A* 2007;143A:1338–41.
- 67 Lazurova I, Macejova Z, Benhatchi K, *et al.* Efficacy of intravenous immunoglobulin treatment in lupus erythematosus chorea. *Clin Rheumatol* 2007;26:2145–7.
- 68 Usugi T, Nakano K, Nakayama T, *et al.* Familial antiphospholipid antibody in a child with involuntary movement and deterioration. *Pediatr Int* 2007;49:238–41.
- 69 Wu SW, Graham B, Gelfand MJ, *et al.* Clinical and positron emission tomography findings of chorea associated with primary antiphospholipid antibody syndrome. *Mov Disord* 2007;22:1813–5.
- 70 Carecchio M, Comi C, Varrasi C, *et al.* Complex movement disorders in primary antiphospholipid syndrome: a case report. *J Neurol Sci* 2009;281:101–3.
- 71 Gelosa G, Tremolizzo L, Galbusera A, *et al.* Narrowing the window for “senile chorea”: a case with primary antiphospholipid syndrome. *J Neurol Sci* 2009;284:211–3.
- 72 Demonty J, Gonce M, Ribai P, *et al.* Chorea associated with antiphospholipid antibodies: case report. *Acta Clin Belg* 2010;65:350–3.
- 73 Dale RC, Yin K, Ding A, *et al.* Antibody binding to neuronal surface in movement disorders associated with lupus and antiphospholipid antibodies. *Dev Med Child Neurol* 2011;53:522–8.
- 74 Albishri JA. Chorea as a first manifestation in young patients with systemic lupus erythematosus who was initially diagnosed with rheumatic fever. *Clin Med Insights Case Rep* 2012;5:19–21.
- 75 Ariizumi Y, Ozawa T, Tokutake T, *et al.* Chorea as the first sign in a patient with elderly-onset systemic lupus erythematosus. *Case Rep Neurol Med* 2012;2012:317082.
- 76 Ayalew Y, Khattak F. Antiphospholipid antibody syndrome presenting with hemichorea. *Case Rep Rheumatol* 2012;2012:471543.
- 77 Poil AR, Yousef Khan F, Lutf A, *et al.* Chorea as the first and only manifestation of systemic lupus erythematosus. *Case Rep Rheumatol* 2012;2012:907402.
- 78 Seiro A de M, Almeida MCF de, Accorsi TAD, *et al.* Association between immunological diseases and their similar clinical manifestations. *Arq Bras Cardiol* 2012;98:e28–31.
- 79 Biernacka-Zielinska M, Lipinska J, Szymanska-Kaluza J, *et al.* Recurrent arterial and venous thrombosis in a 16-year-old boy in the course of primary antiphospholipid syndrome despite treatment with low-molecular-weight heparin: a case report. *J Med Case Rep* 2013;7:221.
- 80 Kuz Tekşut T, Özcan H, Işık M, *et al.* Antiphospholipid syndrome related chorea gravidarum case with psychotic symptoms misdiagnosed as conversion disorder: case report. *Turk Psikiyatri Derg* 2013;24:280–3.
- 81 Ostovan VR, Ghorbani A. Chorea and retinal vessel occlusion in a patient with systemic lupus erythematosus. *Iran J Neurol* 2013;12:66–8.
- 82 De Maeseneire C, Duray MC, Rutgers MP, *et al.* Neurological presentations of the antiphospholipid syndrome: three illustrative cases. *Acta Neurol Belg* 2014;114:117–23.
- 83 Safarpour D, Buckingham S, Jabbari B. n.d. Chorea associated with high titers of antiphospholipid antibodies in the absence of antiphospholipid antibody syndrome. 5:294.
- 84 Schrader C, Aumüller M, Lütjens G, *et al.* Bilateral pallidal stimulation improves chorea in antiphospholipid antibody syndrome with oral anticoagulation. *Mov Disord Clin Pract* 2015;2:194–6.
- 85 Athanasopoulos E, Kalaitzidou I, Vlachaki G, *et al.* Chorea revealing systemic lupus erythematosus in a 13-year old boy: a case report and short review of the literature. *Int Rev Immunol* 2018;37:177–82.
- 86 Dombernowsky NW, Nielsen EN, Law I, *et al.* Beneficial effect of intravenous immunoglobulin treatment in a patient with antiphospholipid syndrome associated chorea. *J Neurol Sci* 2018;390:52–3.
- 87 Yelam A, Bollu PC. An unusual case of antiphospholipid syndrome presenting as chorea. *Cureus* 2018;10:e3508.
- 88 Yokoyama K, Mori M, Yoshida A. Mycophenolate mofetil therapy for two cases of antiphospholipid antibody-associated chorea. *Mod Rheumatol* 2018;28:709–11.
- 89 Zhang L, Pereira AC. Oromandibular chorea in antiphospholipid syndrome. *Pract Neurol* 2018;18:132–3.

- 90 Sonsöz MR, Tekin RD, Gül A, *et al.* Treatment of Libman-Sacks endocarditis by combination of warfarin and immunosuppressive therapy. *Turk Kardiyol Dern Ars* 2019;47:687–90.
- 91 Wang D-M, Su S, Lin Z-Z, *et al.* Recurrent hemichorea in a patient with diabetes and anti-phospholipid syndrome: a case report. *Chin Med J (Engl)* 2020;133:753–5.
- 92 D'hont A, De Wachter M, Driesen Y, *et al.* Successful rituximab therapy for pediatric antiphospholipid-related chorea: a case report and review of the literature. *Neuropediatrics* 2022;53:366–9.
- 93 Demir S, Keskin A, Sağ E, *et al.* The challenges in diagnosing pediatric primary antiphospholipid syndrome. *Lupus (Los Angel)* 2022;31:1269–75.
- 94 Lerjefors L, Andretta S, Bonato G, *et al.* Antiphospholipid-related chorea: two case reports and role of metabolic imaging. *Mov Disord Clin Pract* 2022;9:516–21.
- 95 Farag M, Hunt BJ, Andrews TC. Antiphospholipid-related chorea. *Pract Neurol* 2023;23:150–2.
- 96 Song G-M, Cui Y-J, Qiao J, *et al.* Systemic lupus erythematosus combined with chorea: report of one case and literature review. *Zhongguo Yi Xue Ke Xue Yuan Xue Bao* 2023;45:161–6.
- 97 Javed F, Piranavan P. Chorea as an initial and solitary manifestation of systemic lupus erythematosus with antiphospholipid syndrome in an elderly man. *BMJ Case Rep* 2024;17:e257086.
- 98 Yu Y-W, Chung C-Y, Chiou Y-H, *et al.* Recurrent hemichorea in an adolescent with systemic lupus erythematosus and previous ipsilateral cerebral infarction. *Int J Rheum Dis* 2024;27:e14886.
- 99 Martinez-Ramirez D, Walker RH, Rodríguez-Violante M, *et al.* Review of hereditary and acquired rare choreas. *Tremor Other Hyperkinet Mov (N Y)* 2020;10:24.
- 100 Cardoso F. Autoimmune choreas. *J Neurol Neurosurg Psychiatry* 2017;88:412–7.
- 101 Ehrlich DJ, Walker RH. Functional neuroimaging and chorea: a systematic review. *J Clin Mov Disord* 2017;4:8.
- 102 Carecchio M, Cantello R, Comi C. Revisiting the molecular mechanism of neurological manifestations in antiphospholipid syndrome: beyond vascular damage. *J Immunol Res* 2014;2014:239398.
- 103 Chapman J, Cohen-Armon M, Shoenfeld Y, *et al.* Antiphospholipid antibodies permeabilize and depolarize brain synaptoneurosome. *Lupus (Los Angel)* 1999;8:127–33.

